

# 1.1 Image-Enhanced Technologies



# Improvements of Endoscopic Imaging: Why? (1)

- **Detection :**
  - minimal color changes
  - minimal relief changes
  
- **Characterization :**
  - analysis of superficial vascular network
  - assessment of mucosal pattern



# Improvements of Endoscopic Imaging: Why? (2)

Characterization :

- benign without malignant potential => no treatment
- benign with malignant potential => endoscopic treatment
- malignant with invasion limited to mucosa and/or sub mucosa => endoscopic treatment or surgery
- malignant with deep invasion into digestive wall => surgery



# Modern Endoscopic Imaging (3)

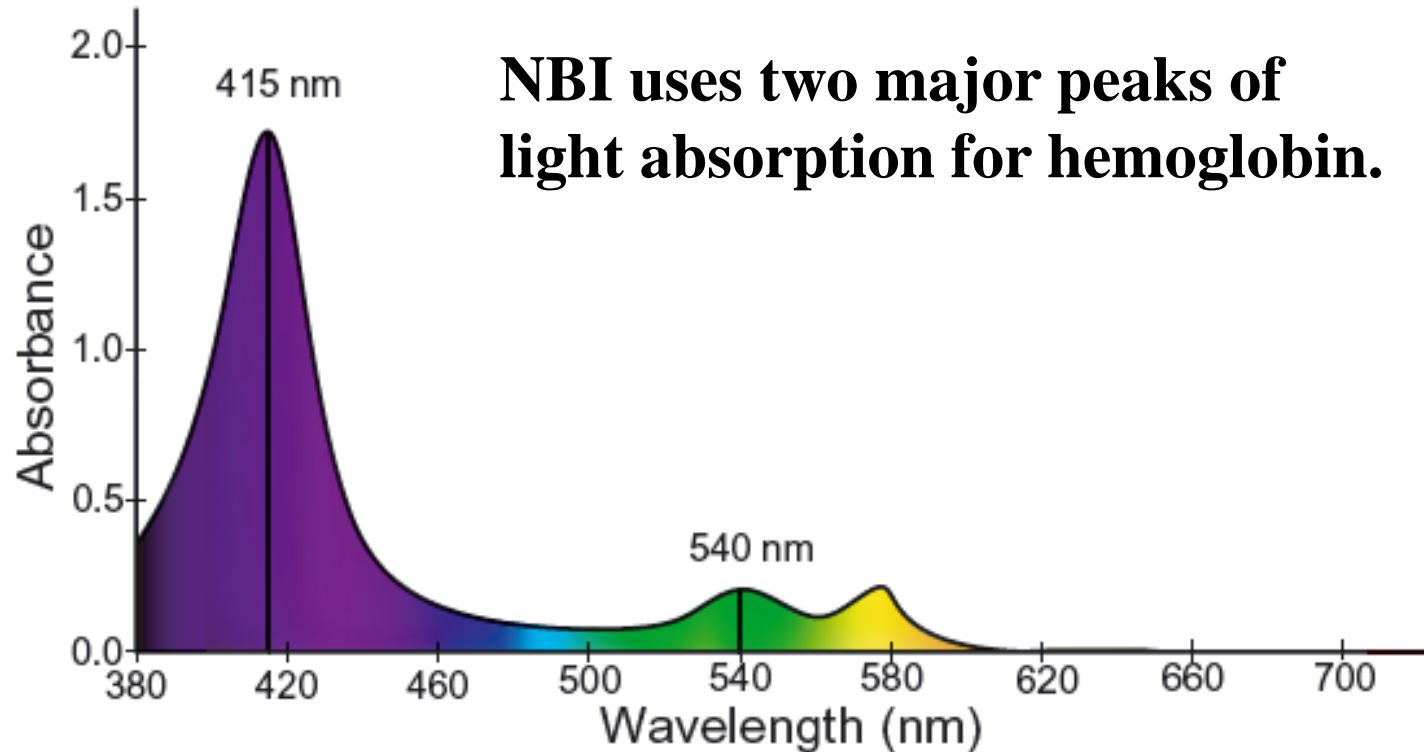
- High-resolution video endoscopes
- Sequential or color CCD
- NBI (Olympus), BLI, CLI (Fujifilms), OE (Pentax)
- Structure enhancement , FICE, I-Scan
- Optical magnification with Zoom or near focused lens
- Wilder field of view



**Narrow Band Imaging (NBI)**  
is designed to improve the **CONTRAST**  
of blood vessels & microvascular  
system vs. surrounding tissue



# Summary of NBI Technology



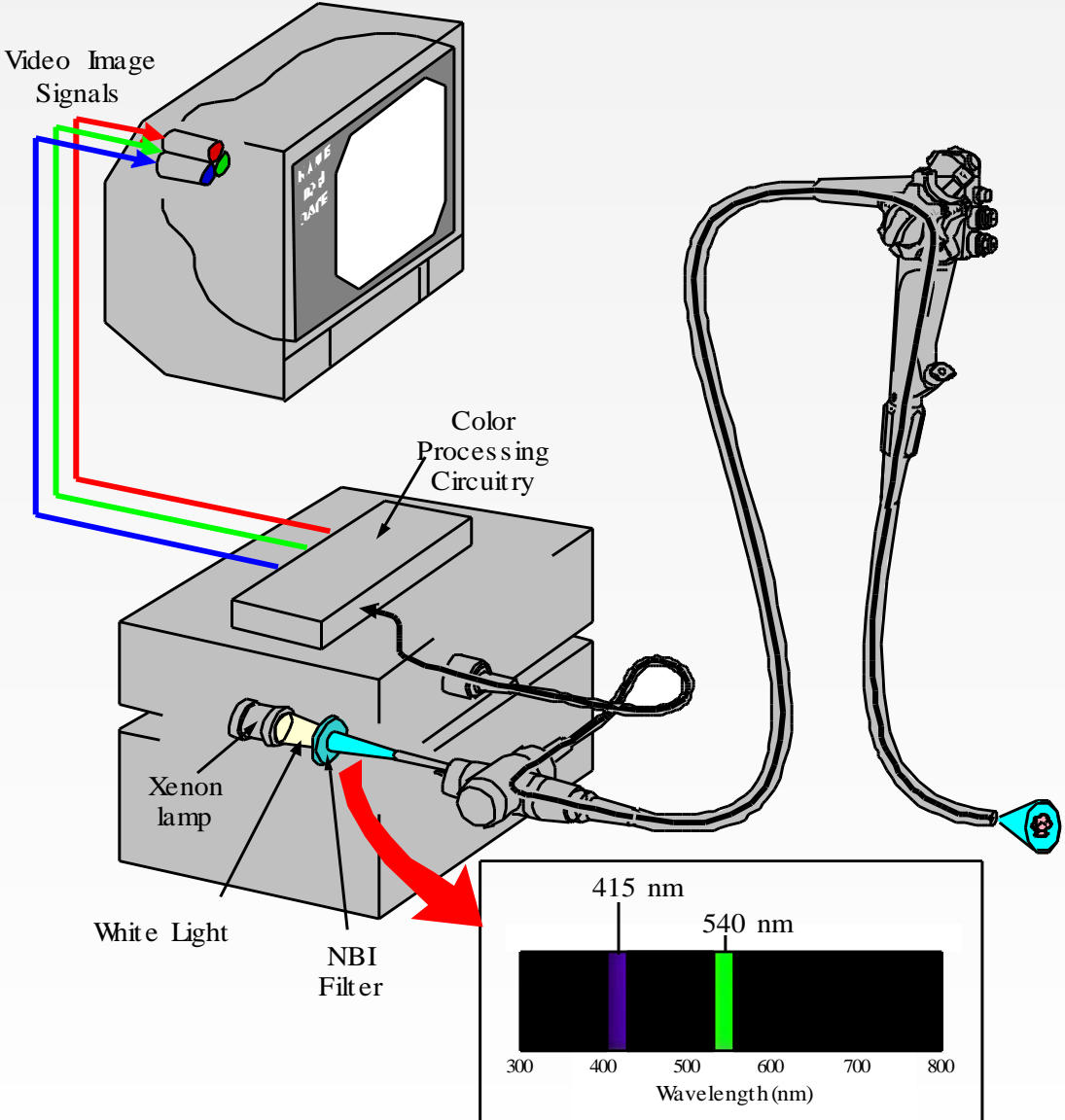
**NBI uses two major peaks of light absorption for hemoglobin.**

Absorbance spectra of oxyhemoglobin.

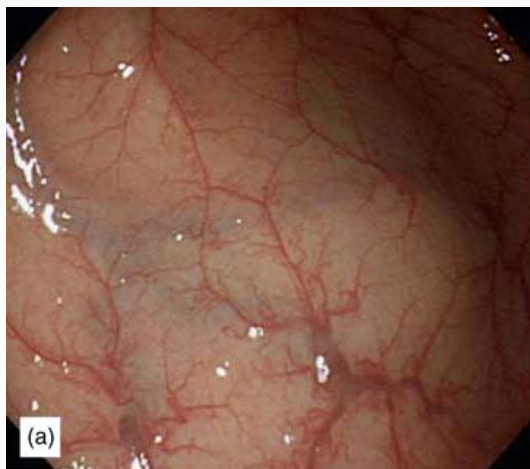
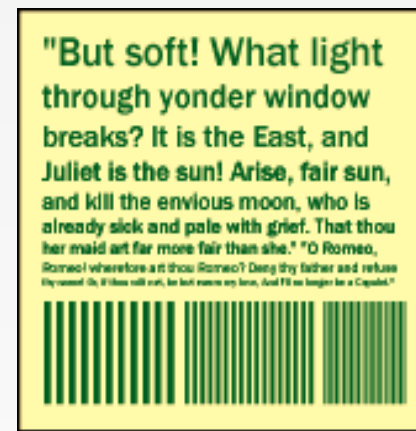
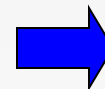
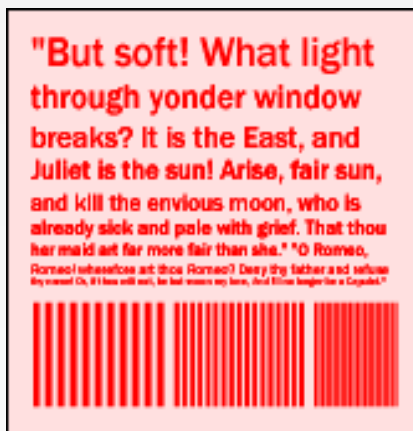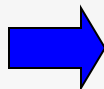

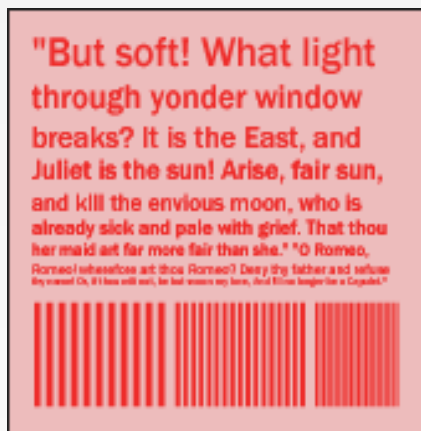
# NBI for Color Chip

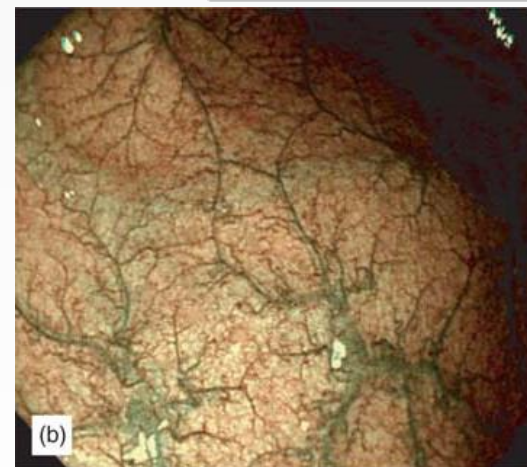
Simultaneous Illumination with 415 nm & 540 nm



## Change Contrast in Luminosity (Brightness)



Copyright: Y. Sano, S. Yoshida



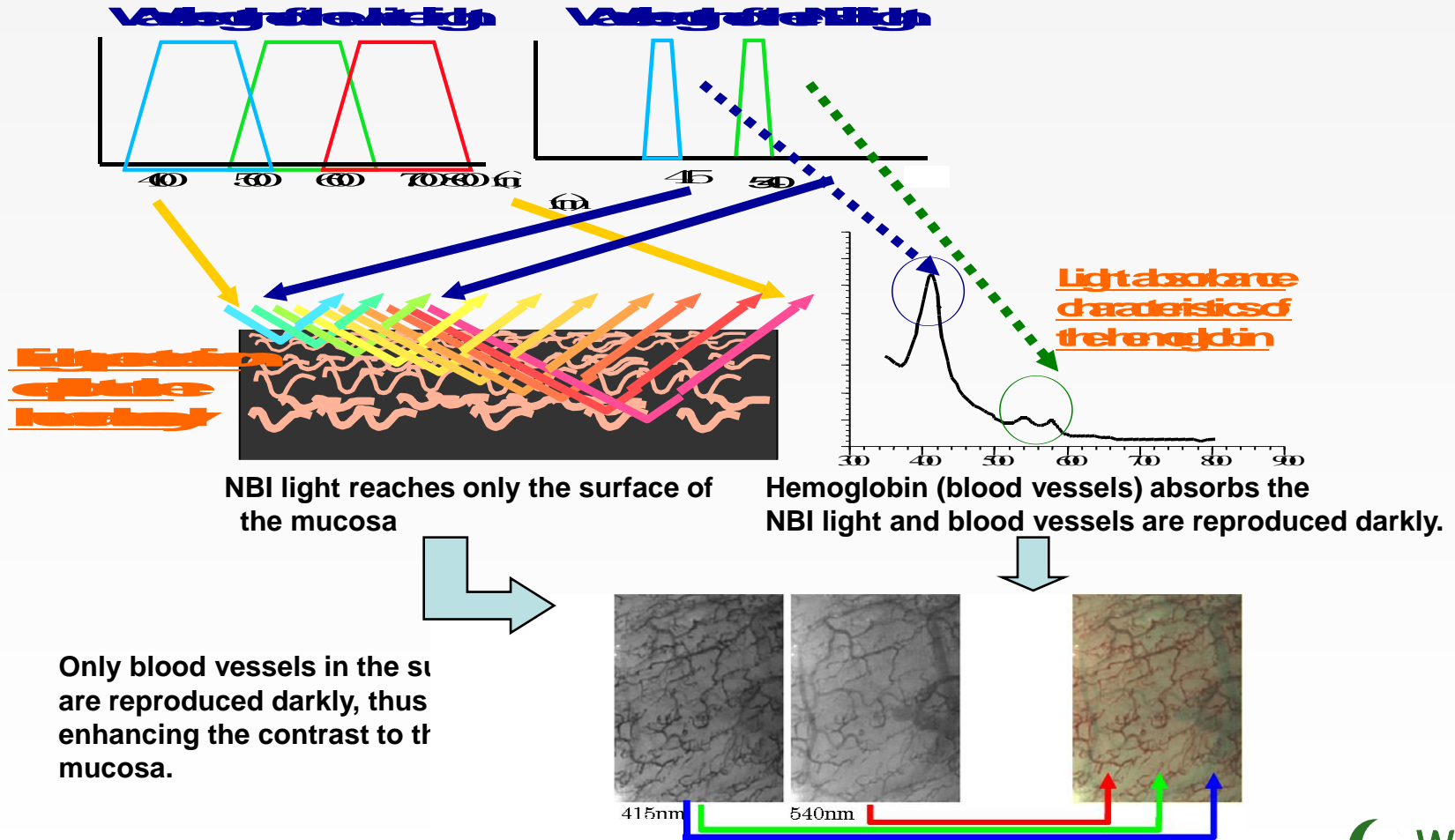
Copyright: Y. Sano, S. Yoshida



# Basic principle of NBI

## How the image is created

Because of the 2 wavelengths in narrow band light, the contrast in the surface is enhanced, and customers can observe the surface and vascular pattern clearly.



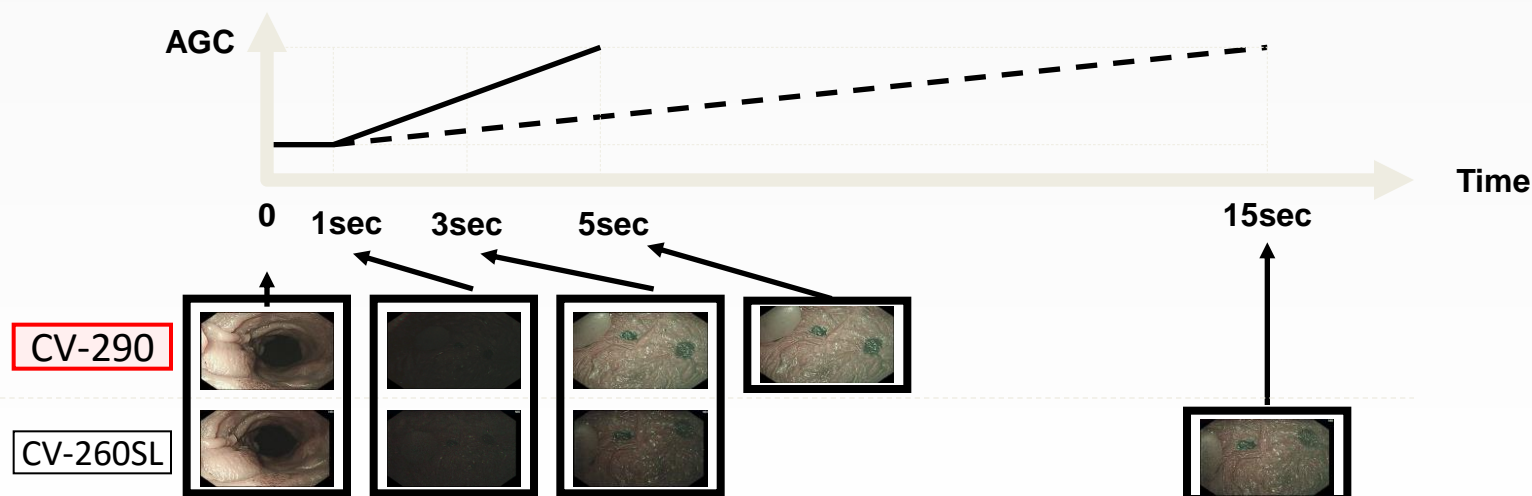
# Improved image quality

## •CV-290: Noise Reduction

•Noise reduction eliminates noise effectively without image deterioration. The conventional noise reduction function was designed to apply fixed noise reduction effect all the time. However, the new noise reduction function is now designed to apply noise reduction effect according to brightness of image. The result is increased effectiveness in noise reduction.

## •CV-290: AGC (Automatic gain control)

•AGC tuning has been adjusted to improve response speed, making the AGC more useful. When moving from a bright area to a dark area, response is now faster, enabling comfortable, stress-free observation.



# Spectrum of potential indications of endoscopy with NBI (1)

<b>Site</b>	<b>Endoscopic criteria</b>	<b>Clinical relevance</b>
Squamous epithelium	<b>Vessels:</b>	<b>Detection + analysis:</b>
In the esophagus	Intrapapillary capillary loops	superficial neoplasia
EG region	<b>Surface morphology:</b>	<b>Diagnosis + surveillance:</b>
Barrett's Esophagus	Intestinal metaplasia Superficial neoplasia	Barrett's esophagus
Gastric mucosa: corpus and antrum	<b>Surface morphology:</b> pit pattern	<b>Detection + analysis:</b> superficial neoplasia
	<b>Vessels:</b> Capillaries Collecting veinules	<b>Detection + analysis:</b> H pylori infection Chronic gastritis



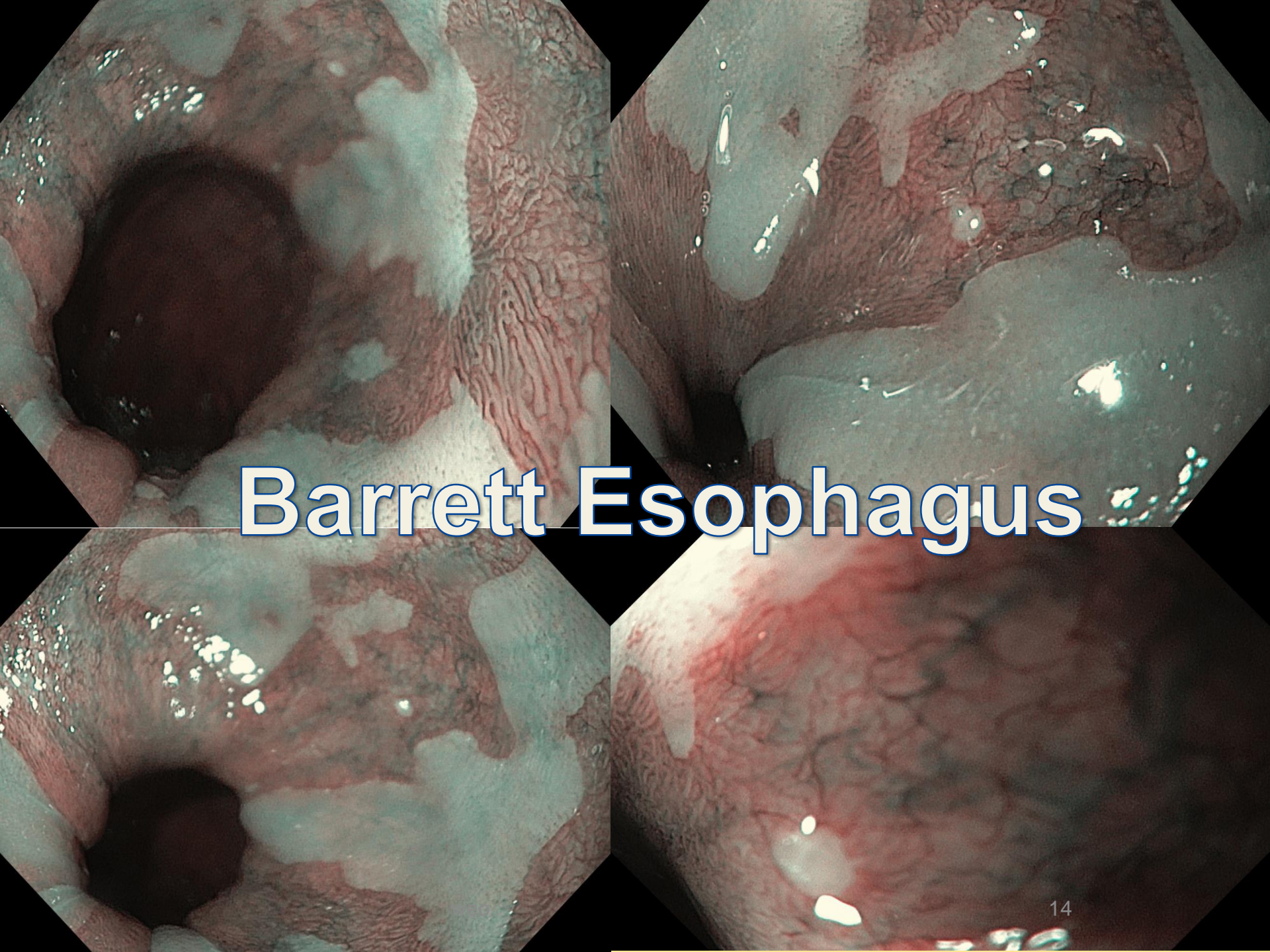
## Spectrum of potential indications of endoscopy with NBI (2)

<b><u>Site relevance</u></b>	<b><u>Endoscopic criteria</u></b>	<b><u>Clinical</u></b>
Duodenal mucosa	<b>Surface morphology:</b>  Atrophy of intestinal villi	<b>Diagnosis:</b>  Gluten enteropathy
Colonic mucosa	<b>Surface morphology:</b>  pit pattern  <b>Vessels:</b>  Capillaries pattern	<b>Detection + analysis:</b>  superficial neoplasia  <b>Analysis :</b>  Ulcerative colitis



# NBI examples





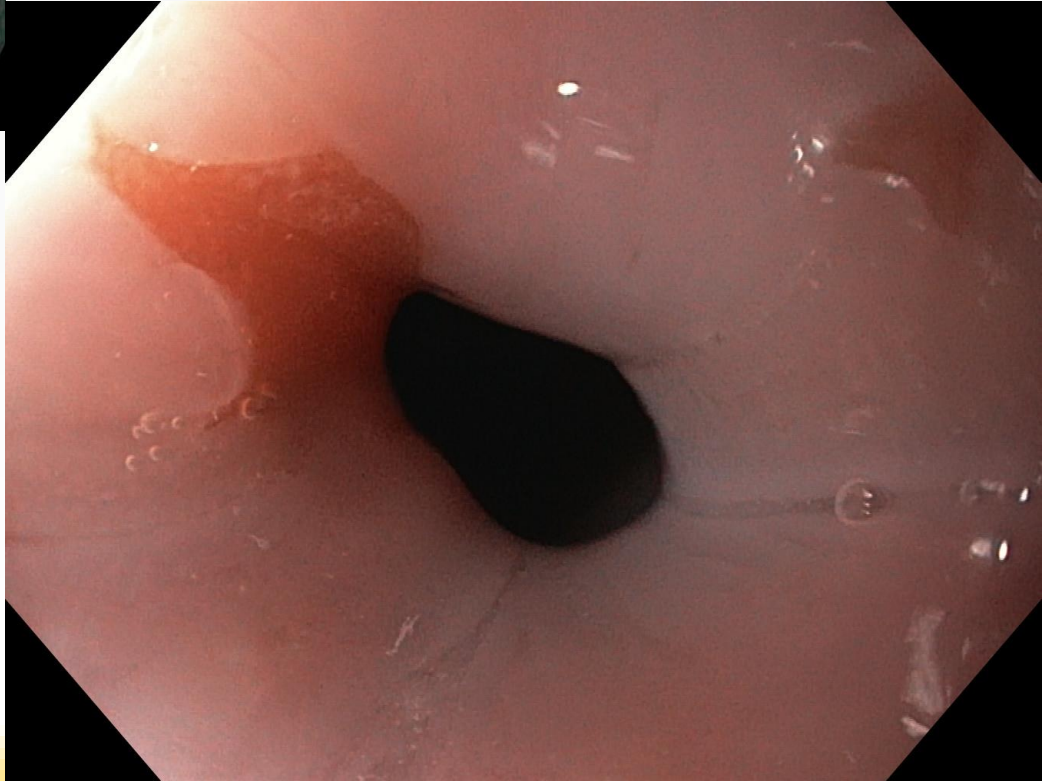
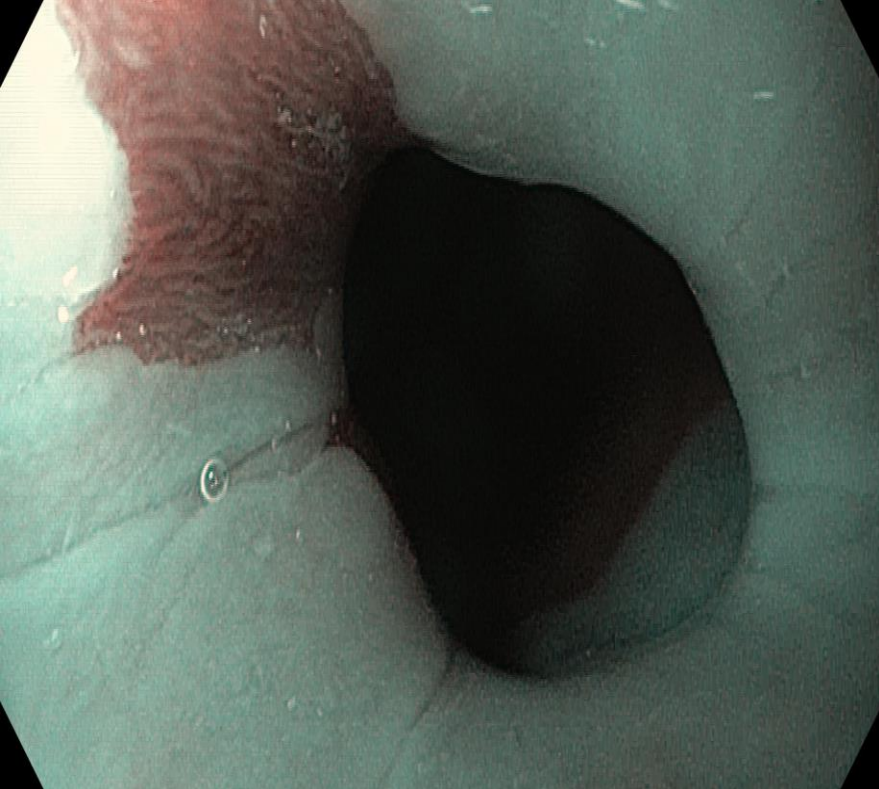
# Barrett Esophagus

The image is a composite of four endoscopic views of the esophagus, arranged in a 2x2 grid. Each view shows the mucosal lining of the esophagus. The top-left view shows a reddish, velvety mucosa with some white patches. The top-right view shows a similar mucosa with more extensive white patches and some bubbles. The bottom-left view shows a reddish mucosa with a network of white lines and patches. The bottom-right view shows a reddish mucosa with a large white patch. The text "Barrett Esophagus" is overlaid in the center in a white, bold, sans-serif font with a blue outline. In the bottom-left image, there is a small white text "weo" in the lower right corner. In the bottom-right image, there is a small white text "15" in the lower right corner.

# Barrett Esophagus

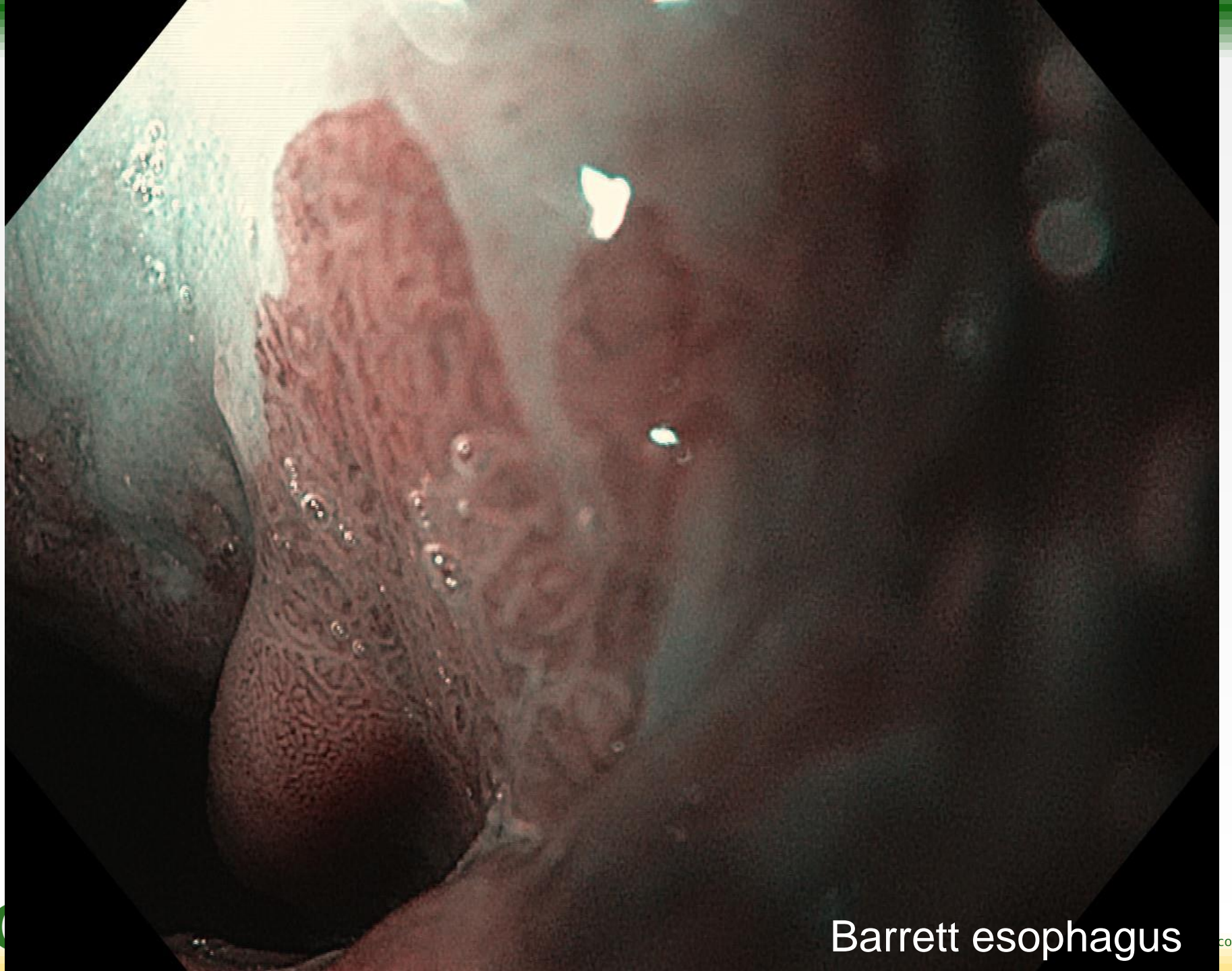
weo

15



Barrett esophagus



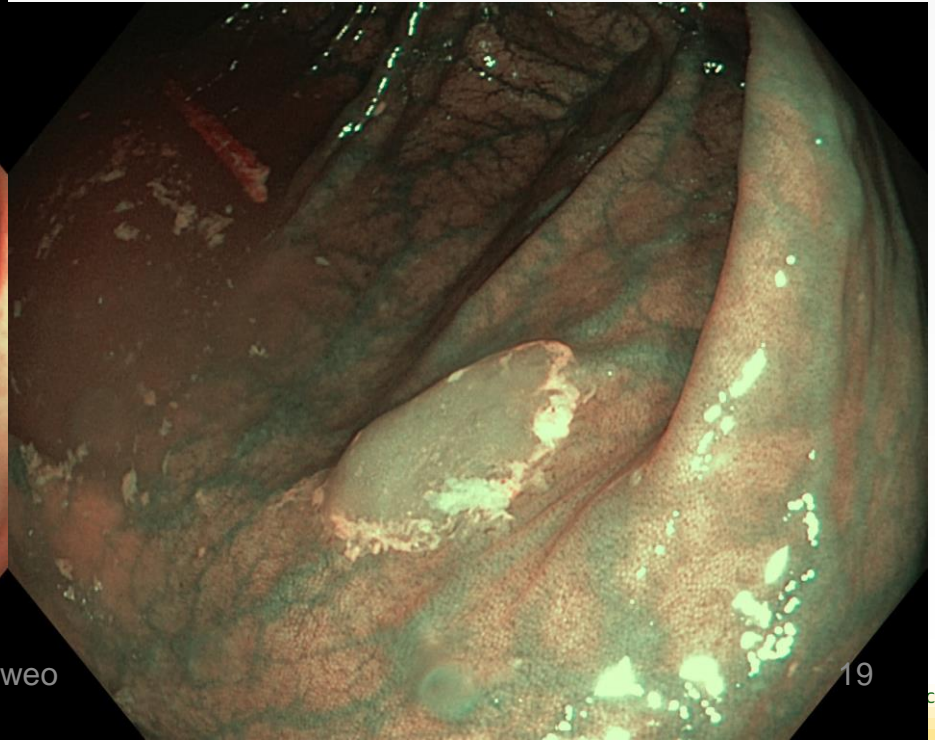
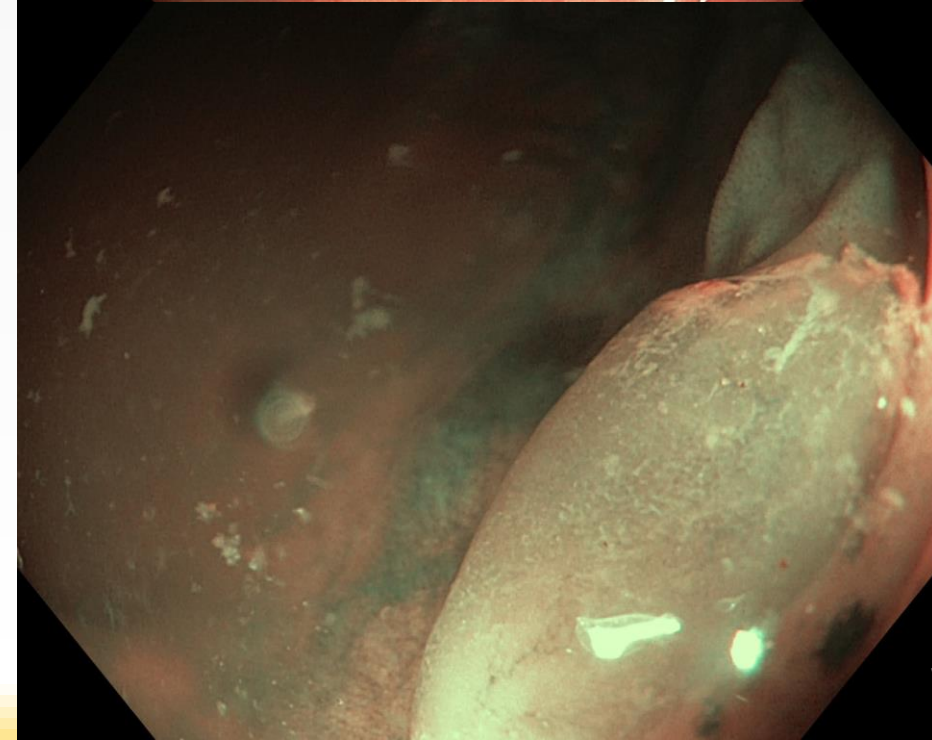
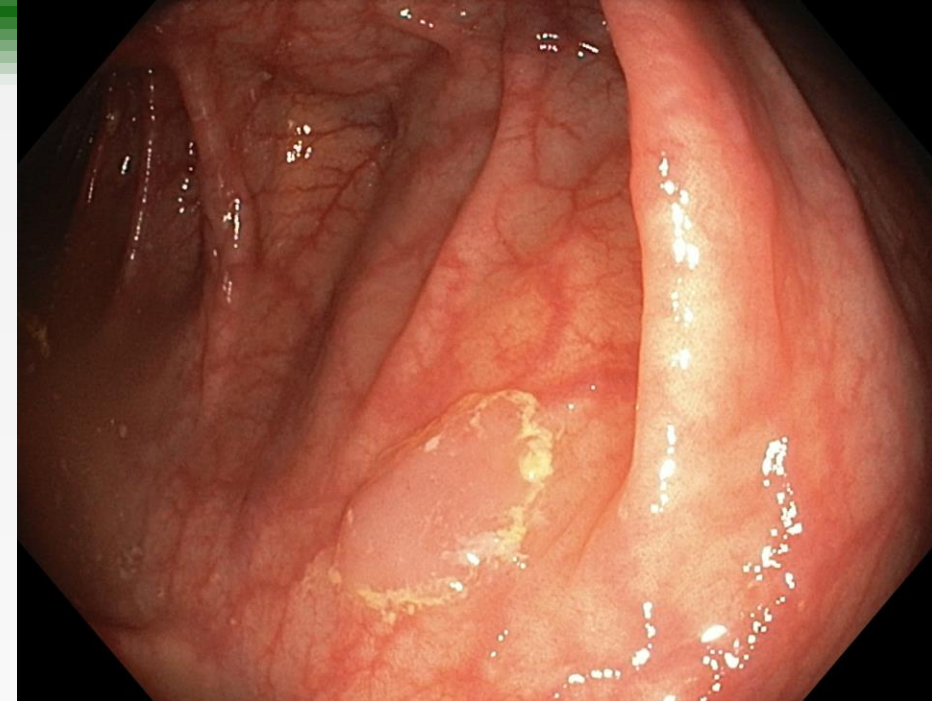


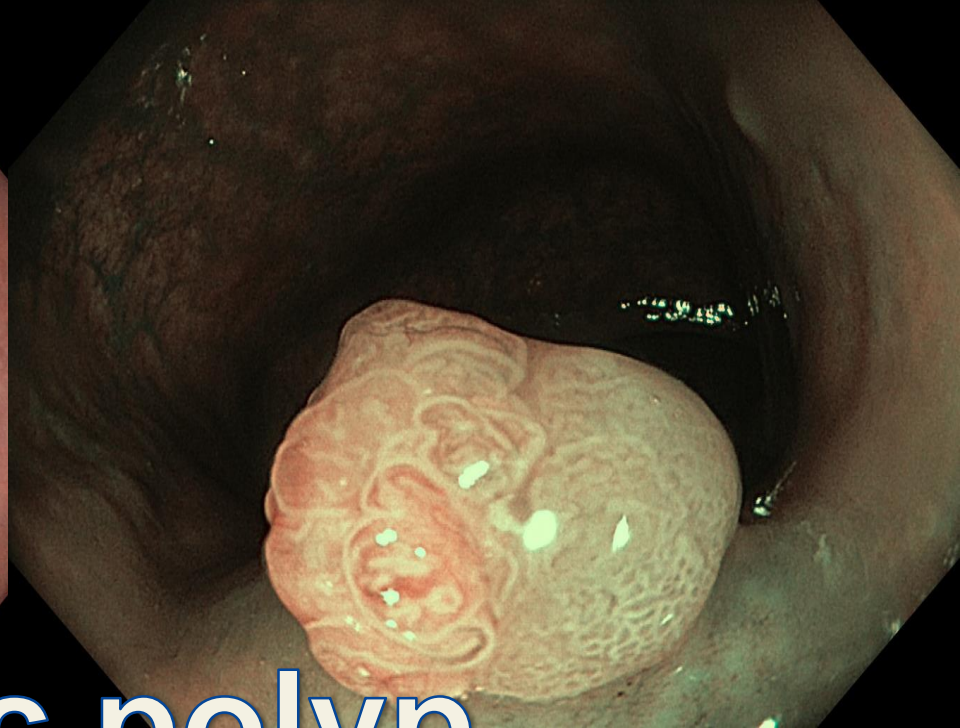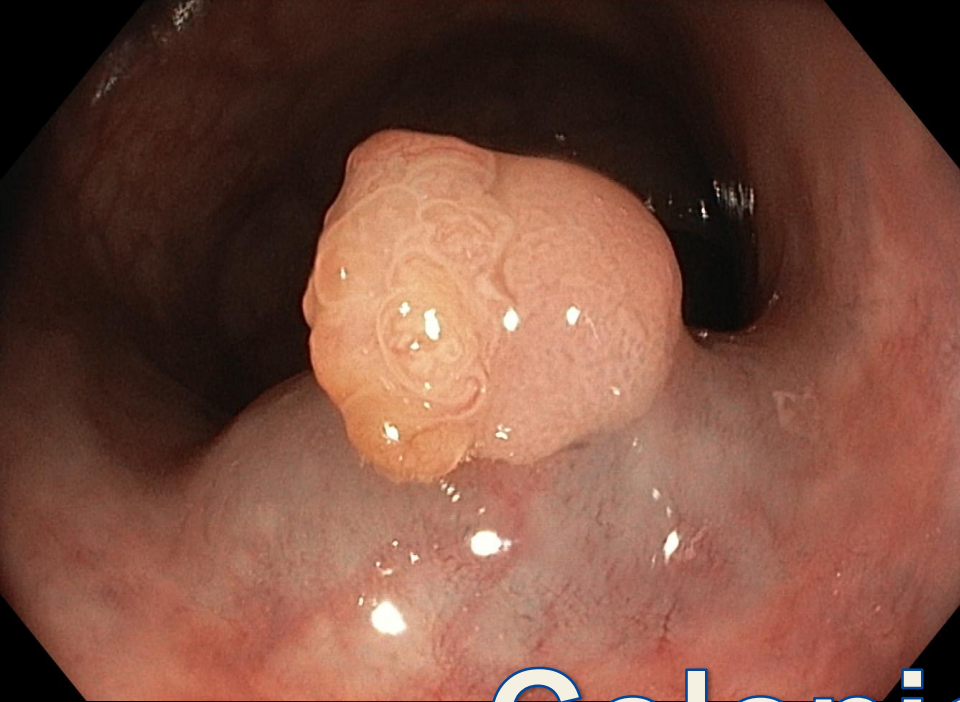
Barrett esophagus



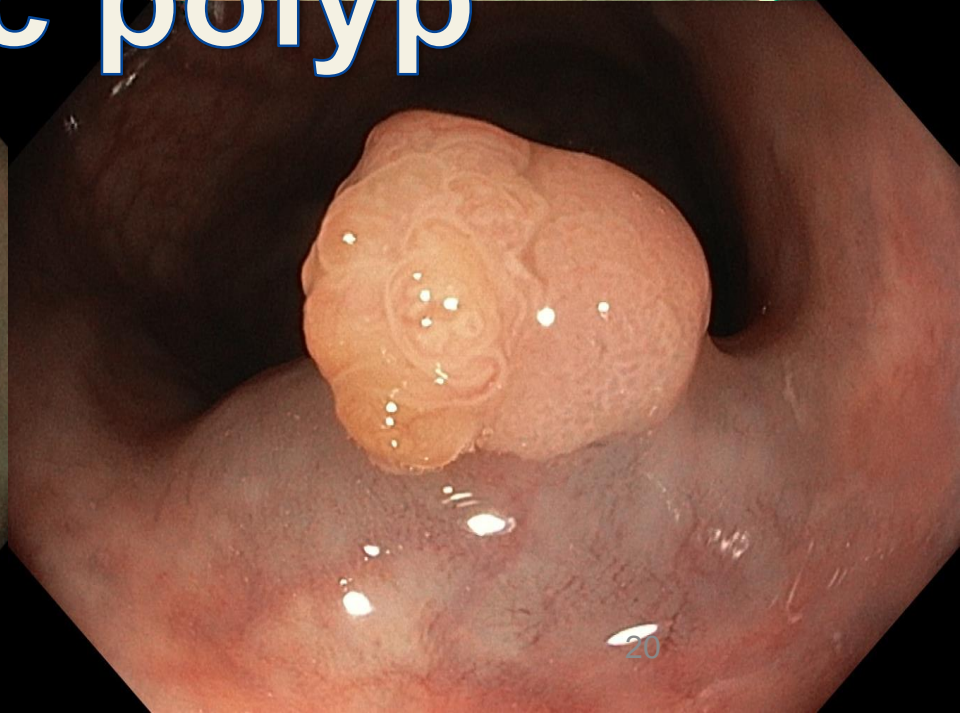
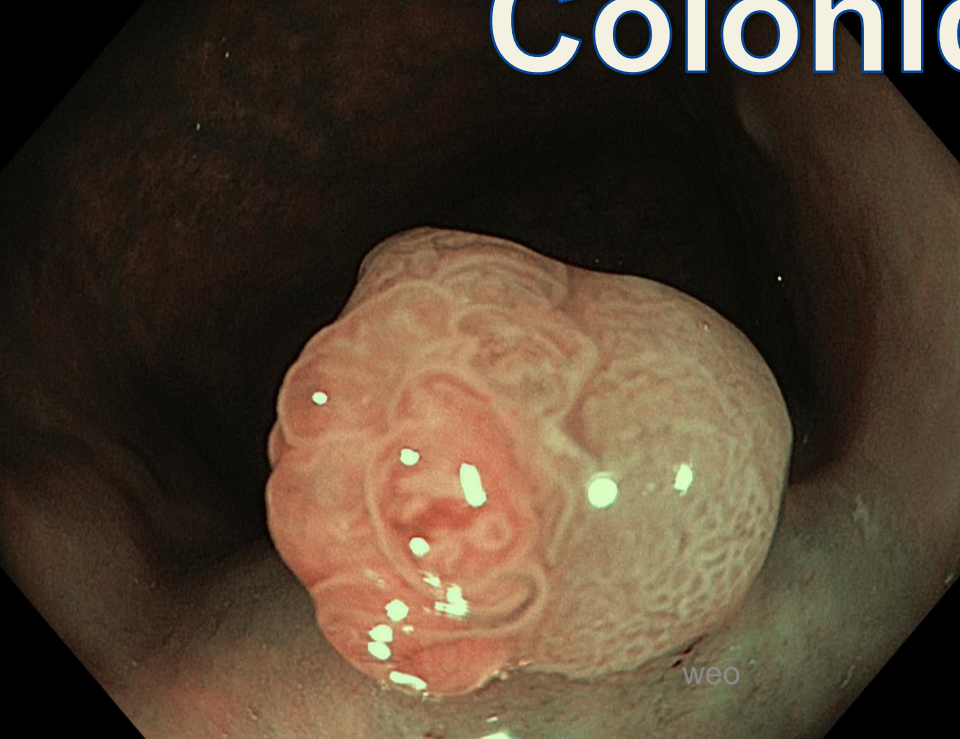
gastritis

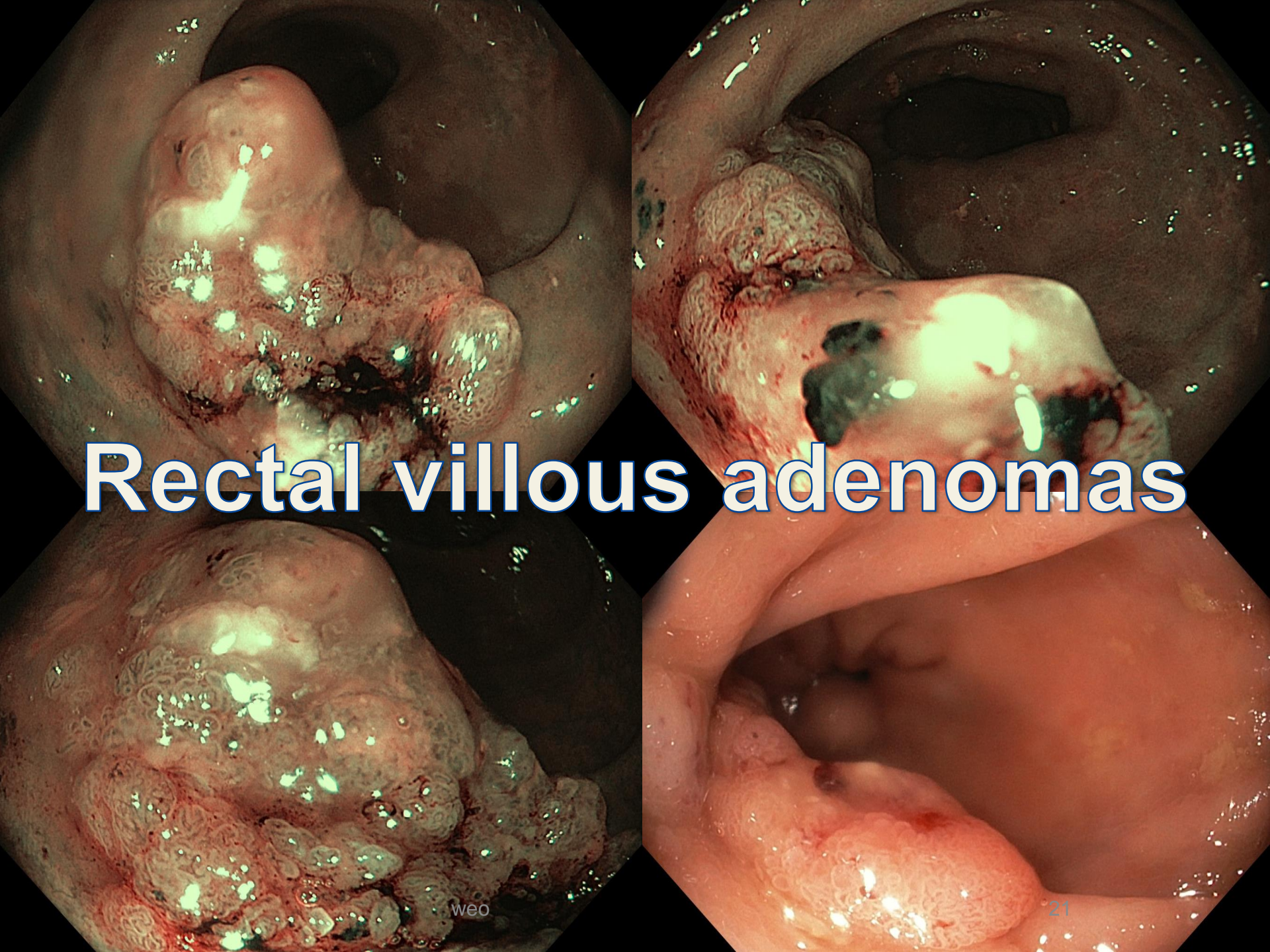
# Sessile serrated adenomas





# Colonic polyp





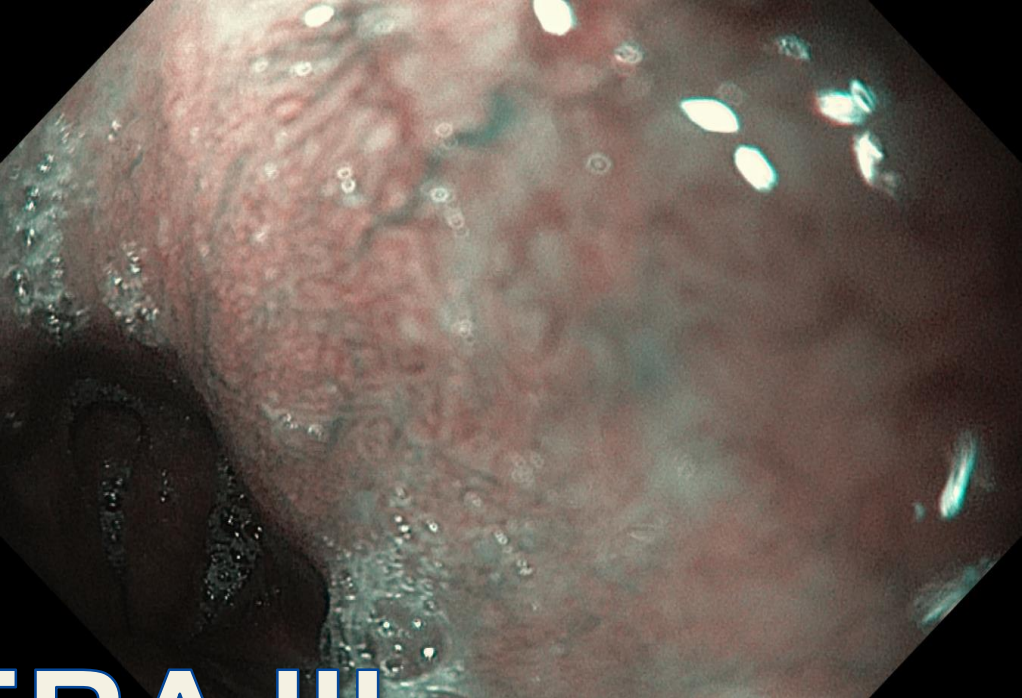
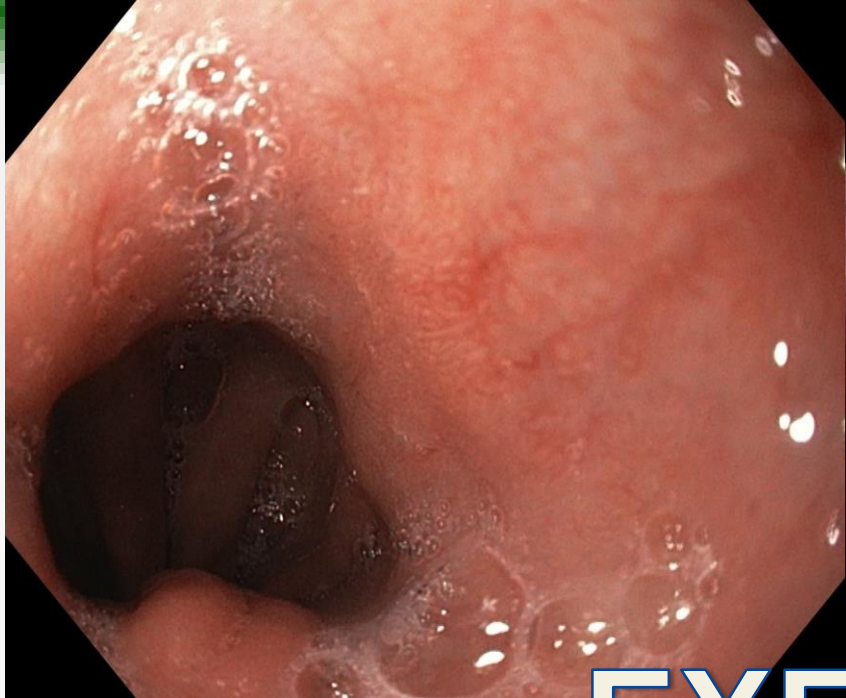
# Rectal villous adenomas

weo

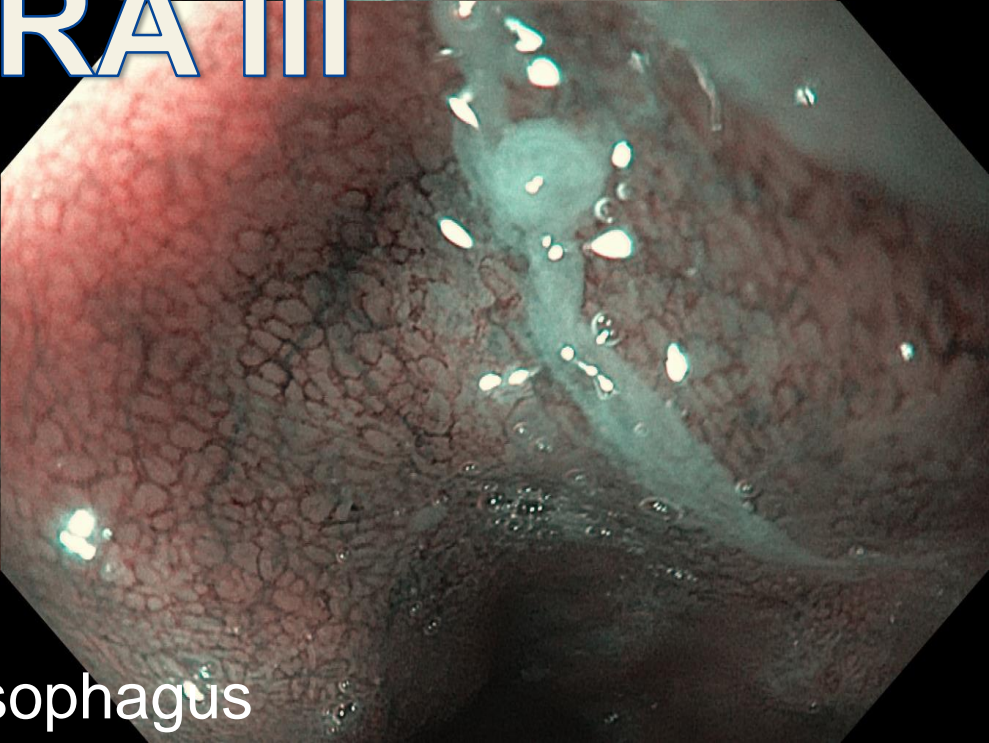
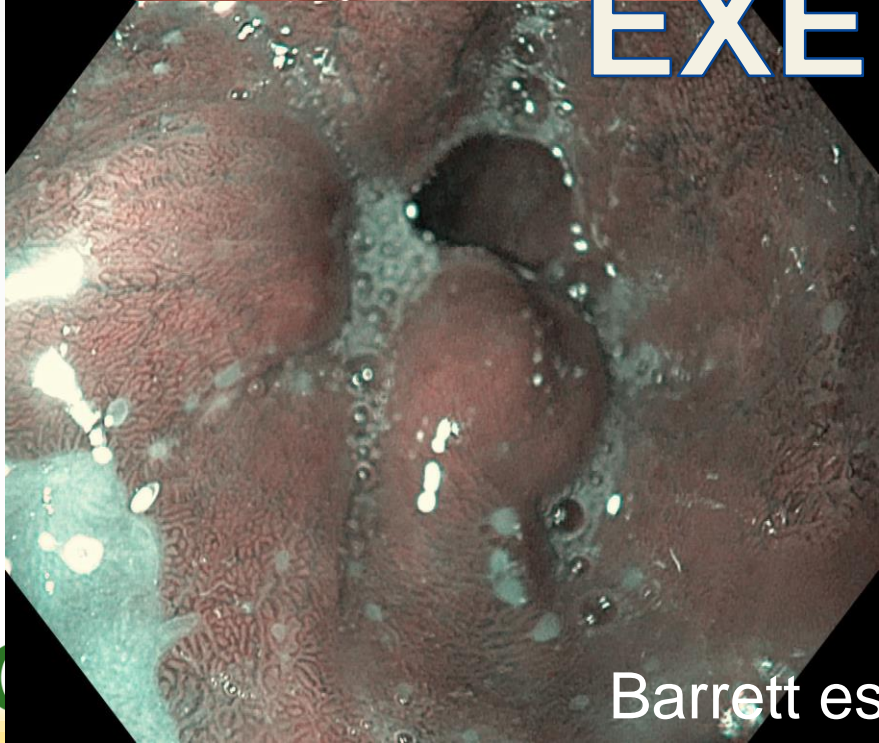
21

# NBI with EXERA III


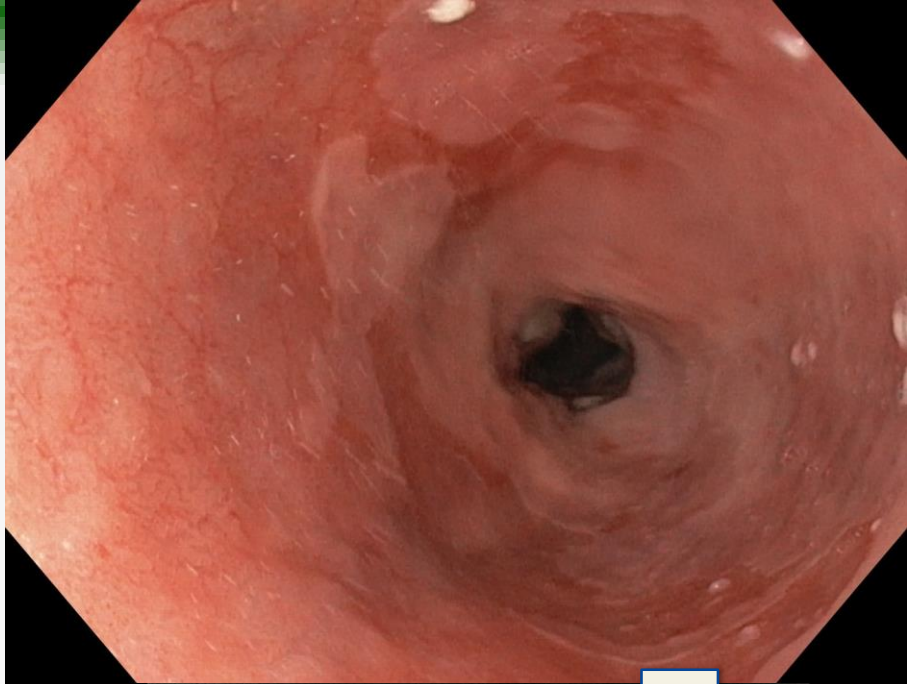



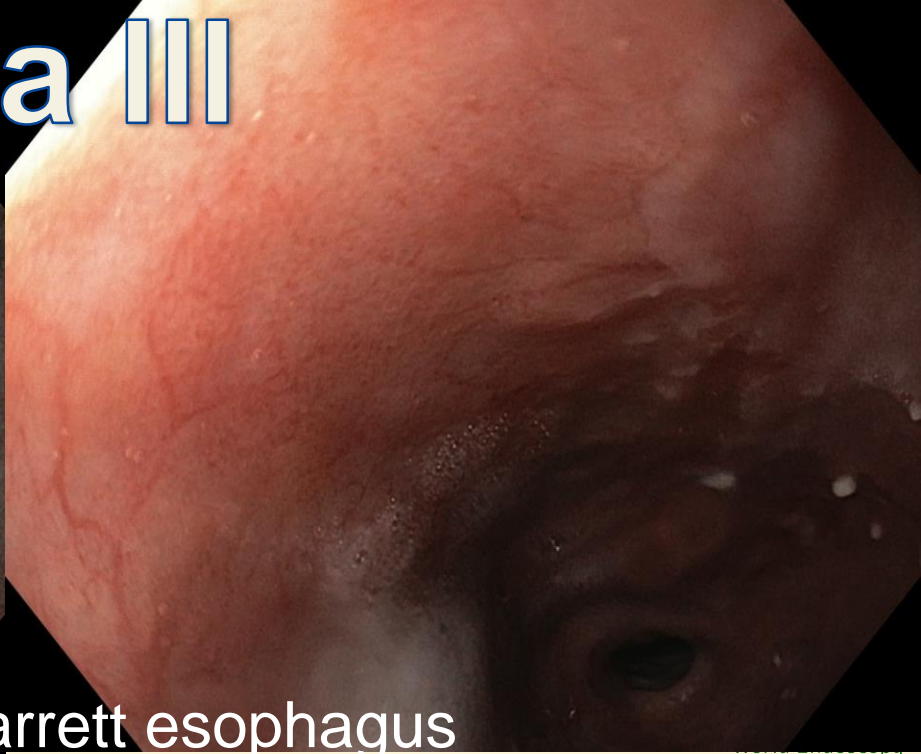
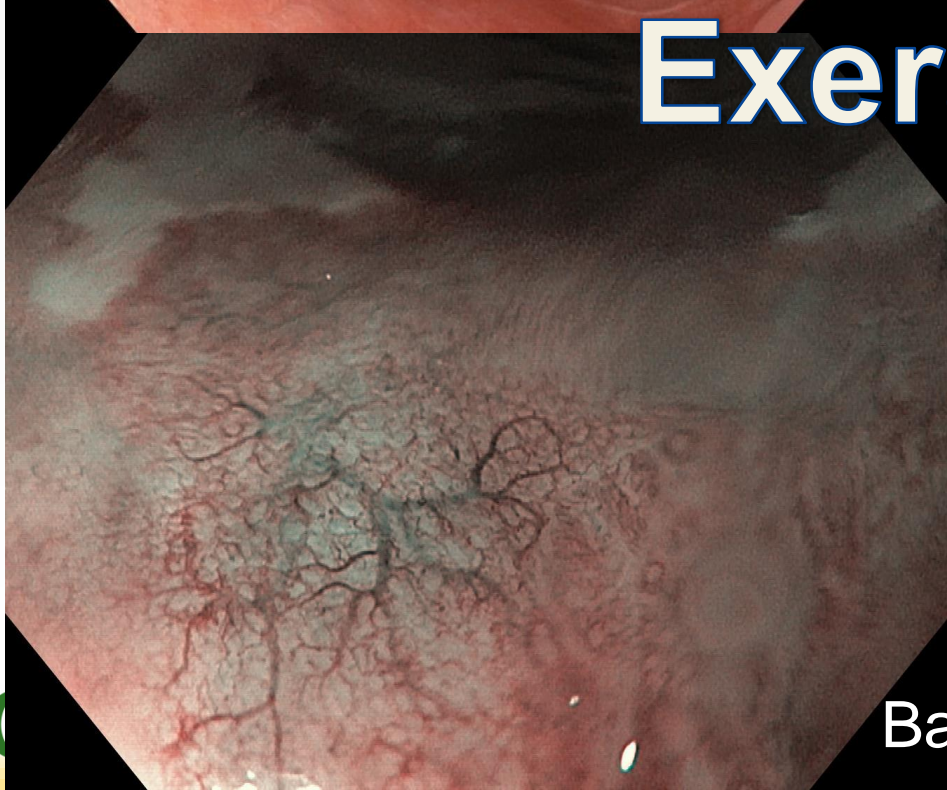
# EXERA III



Barrett esophagus

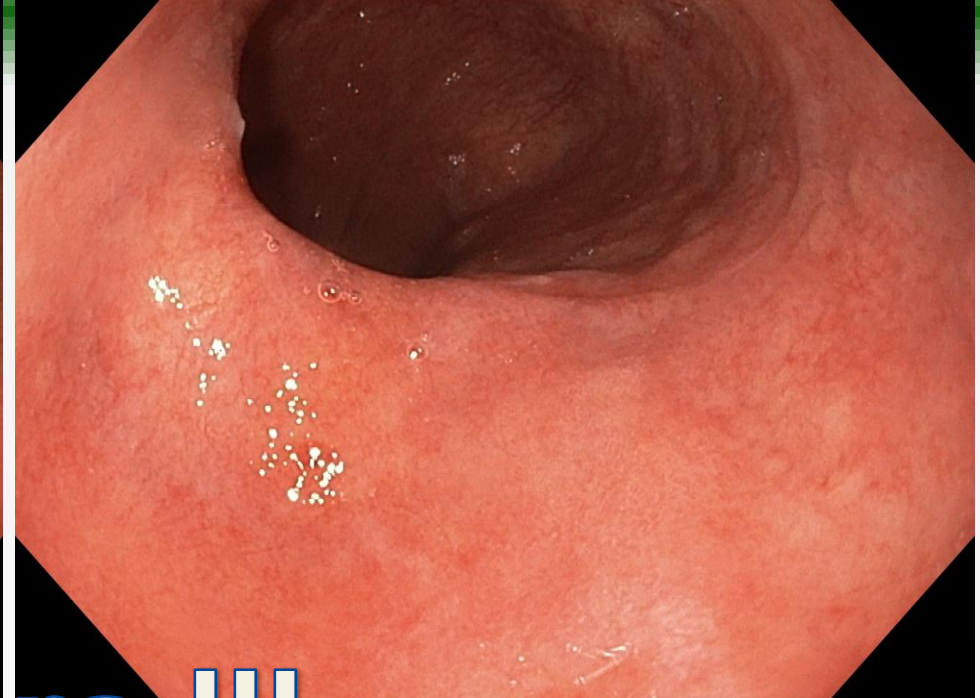
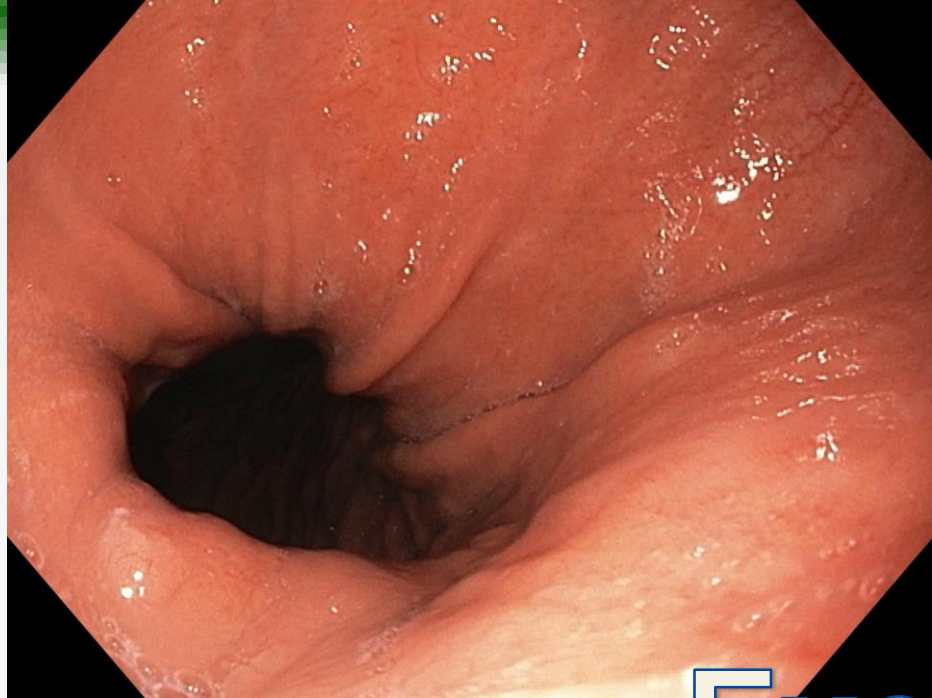


# Exera III

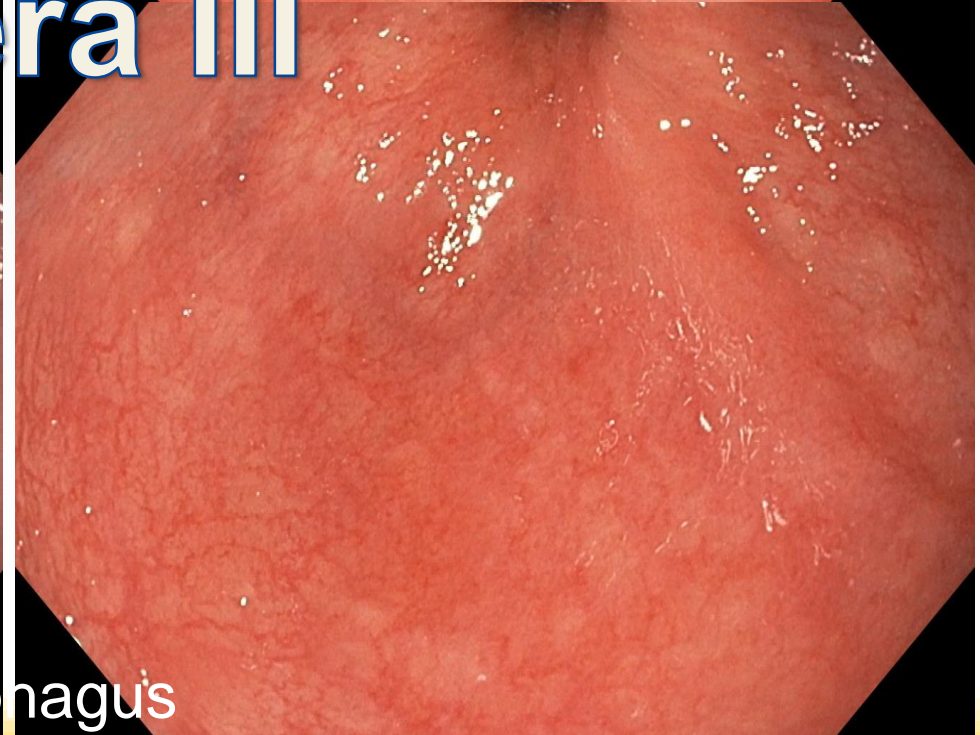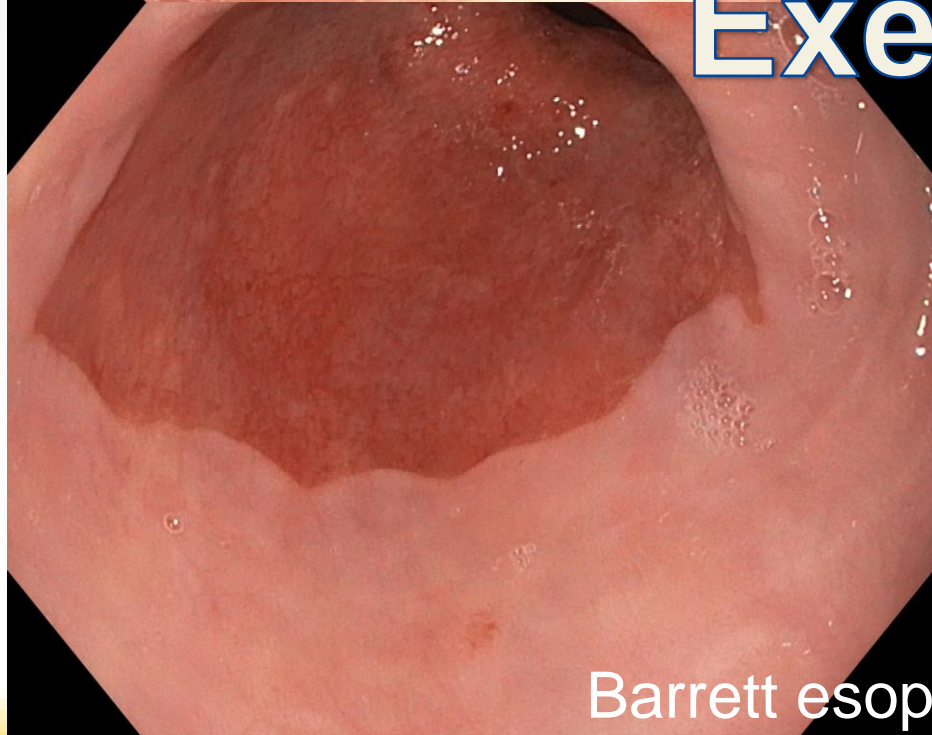


Barrett esophagus

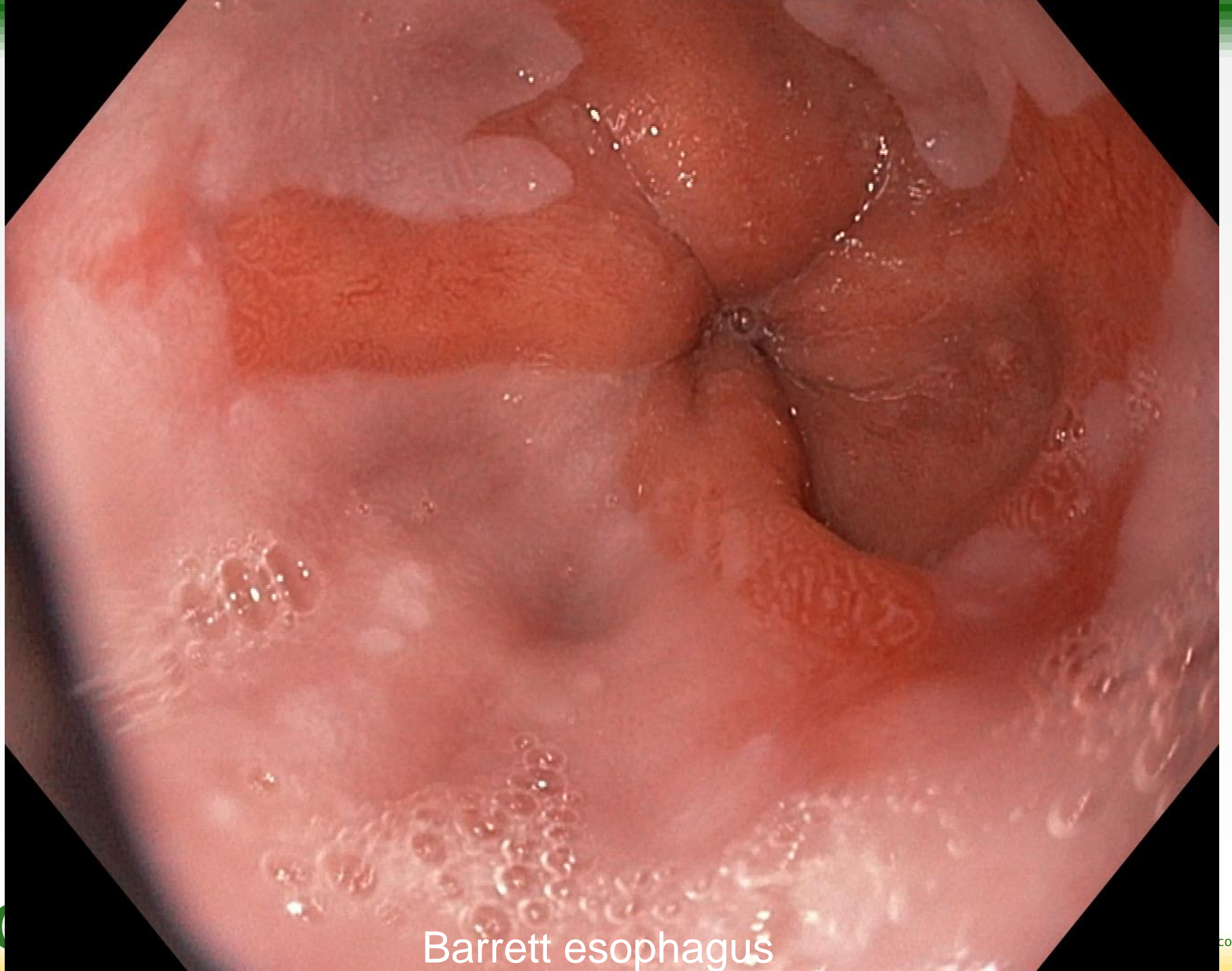




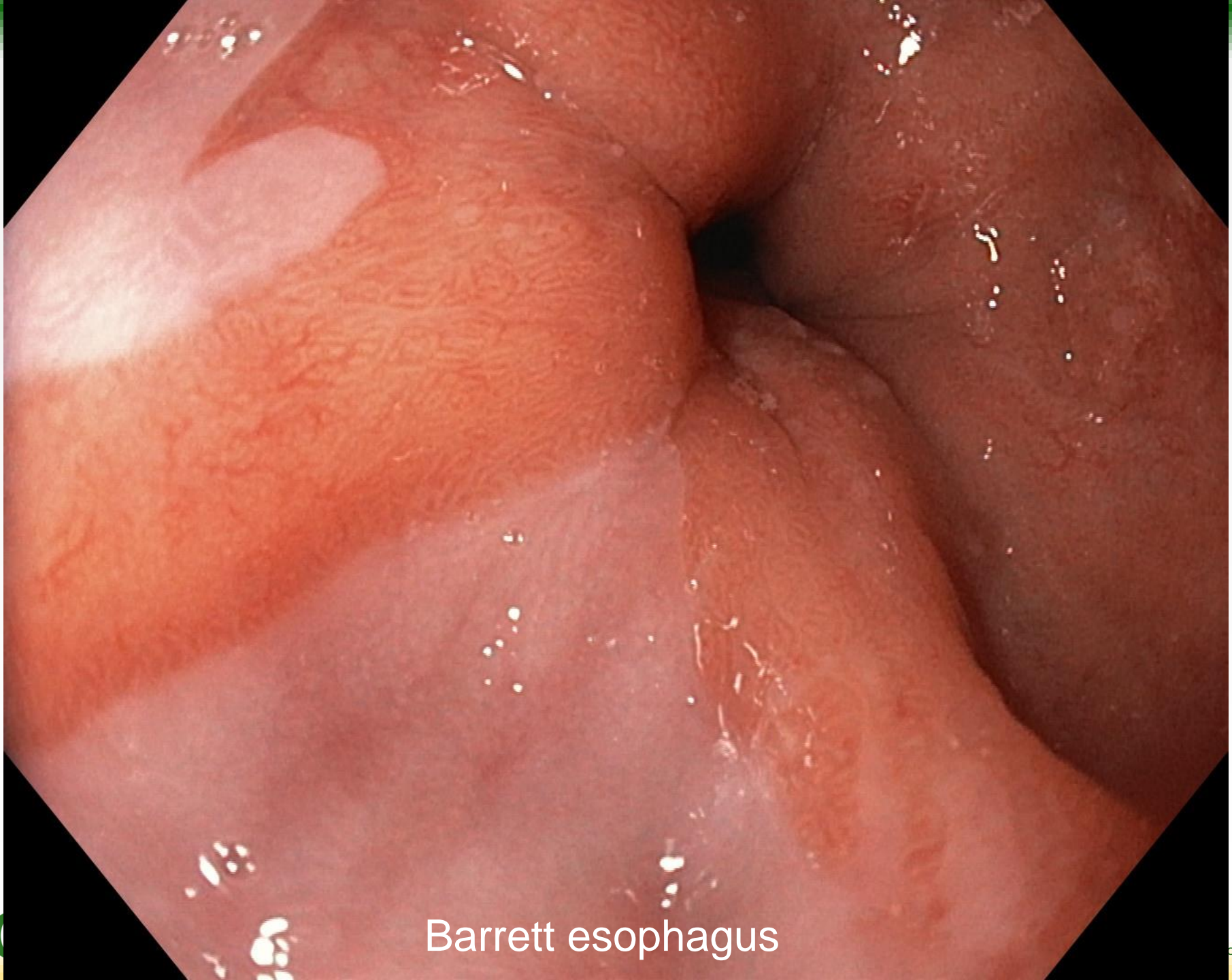
# Exera III



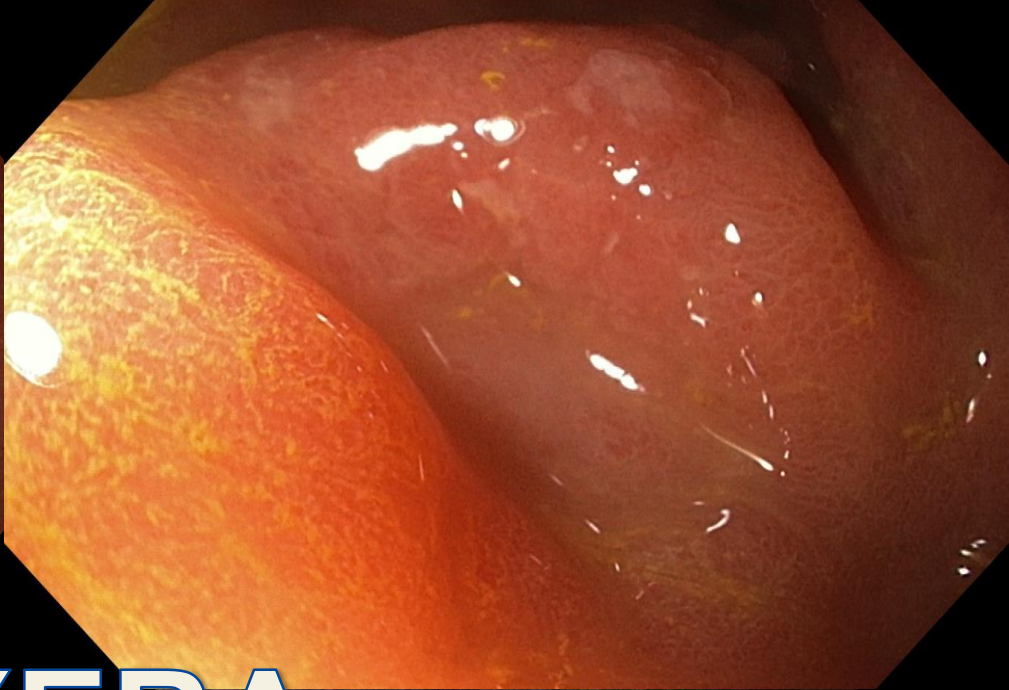
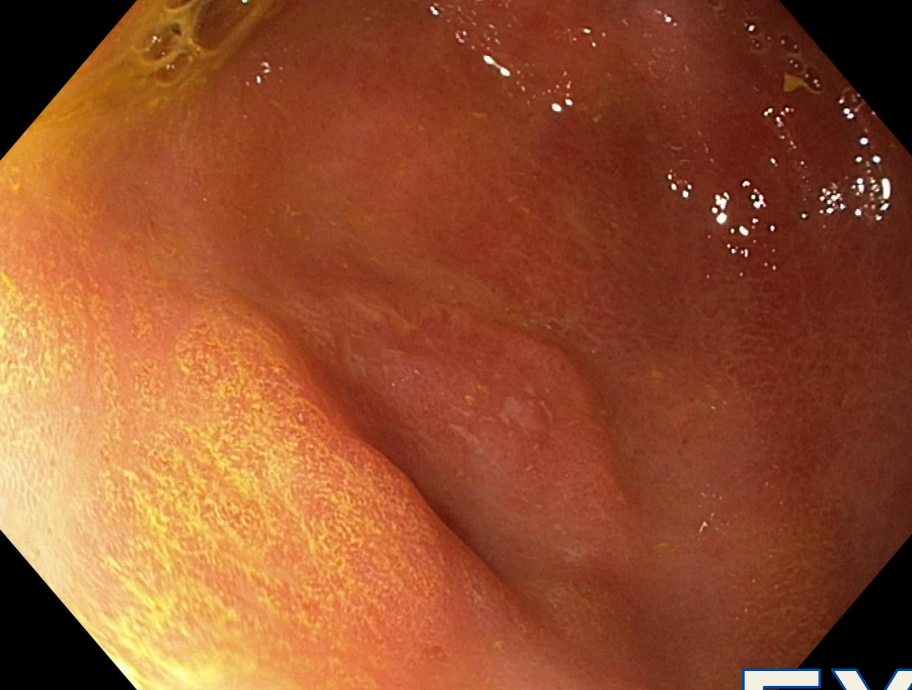Barrett esophagus



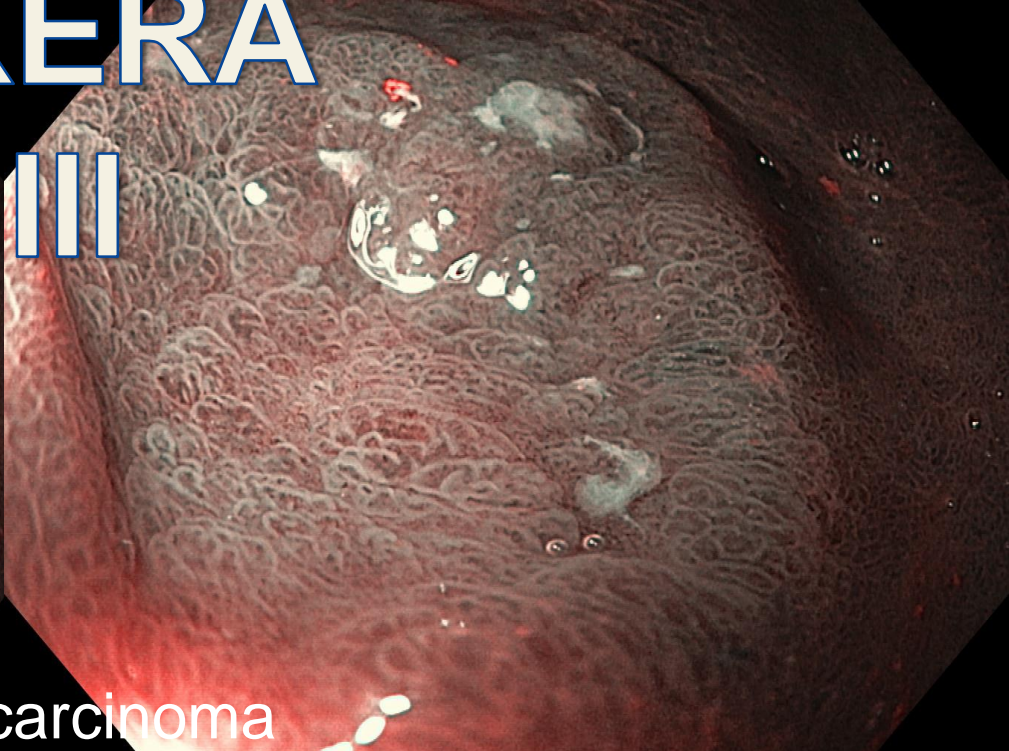
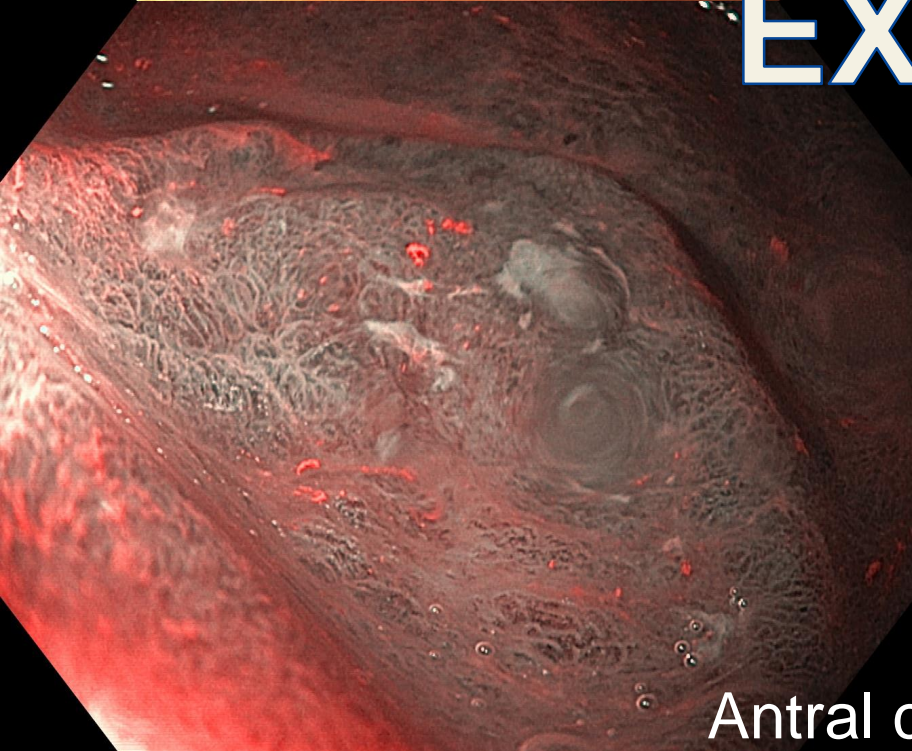
Barrett esophagus



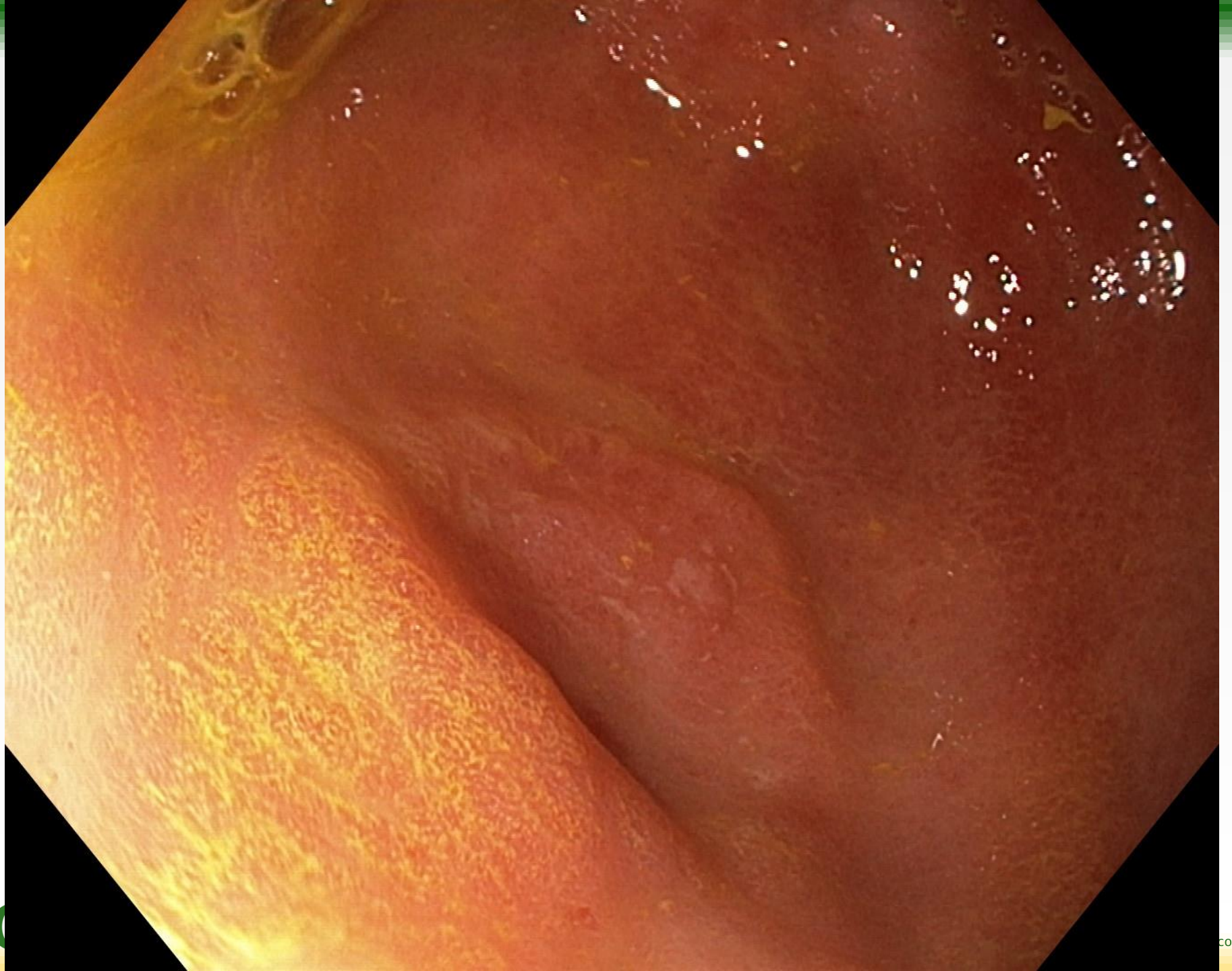Barrett esophagus

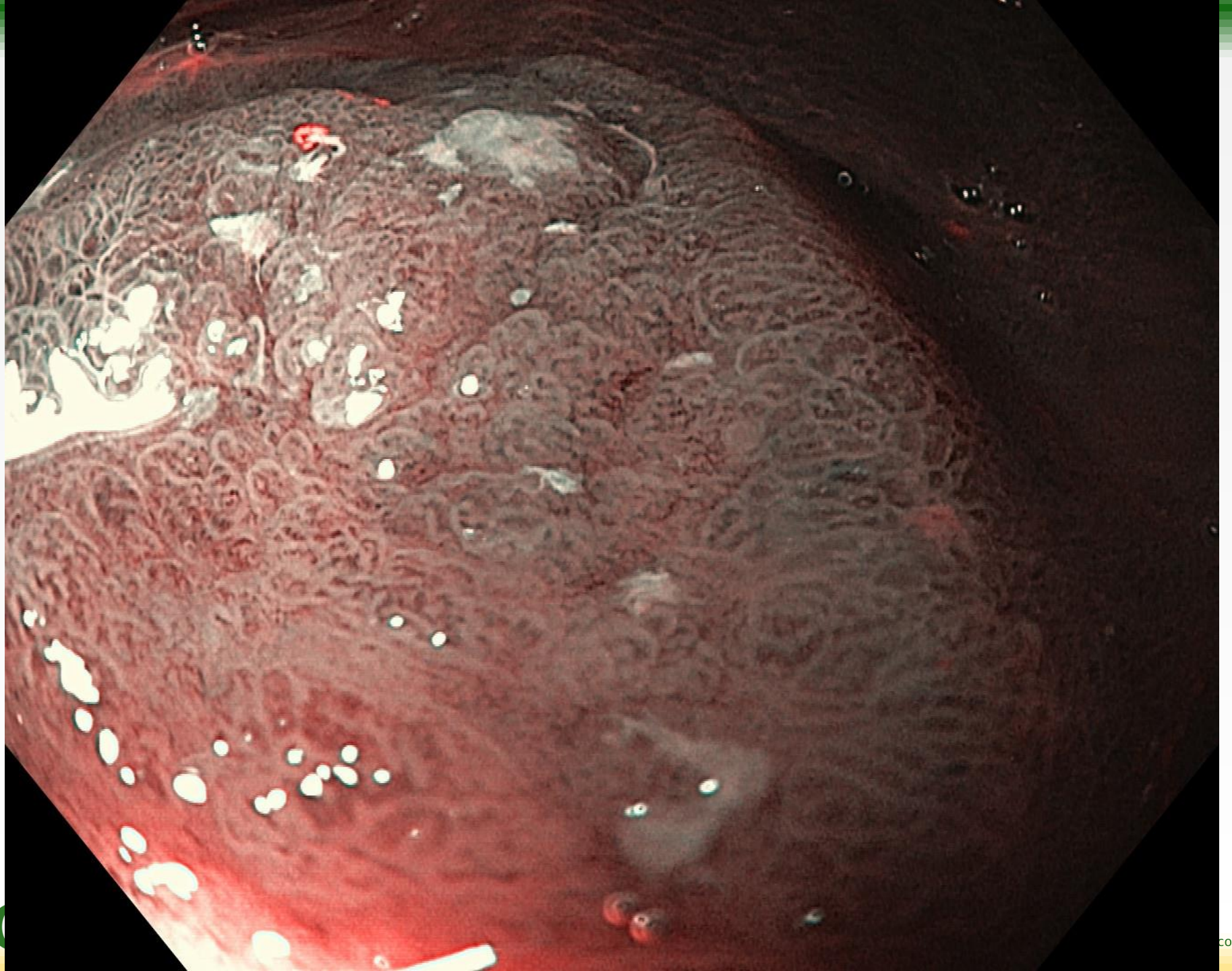


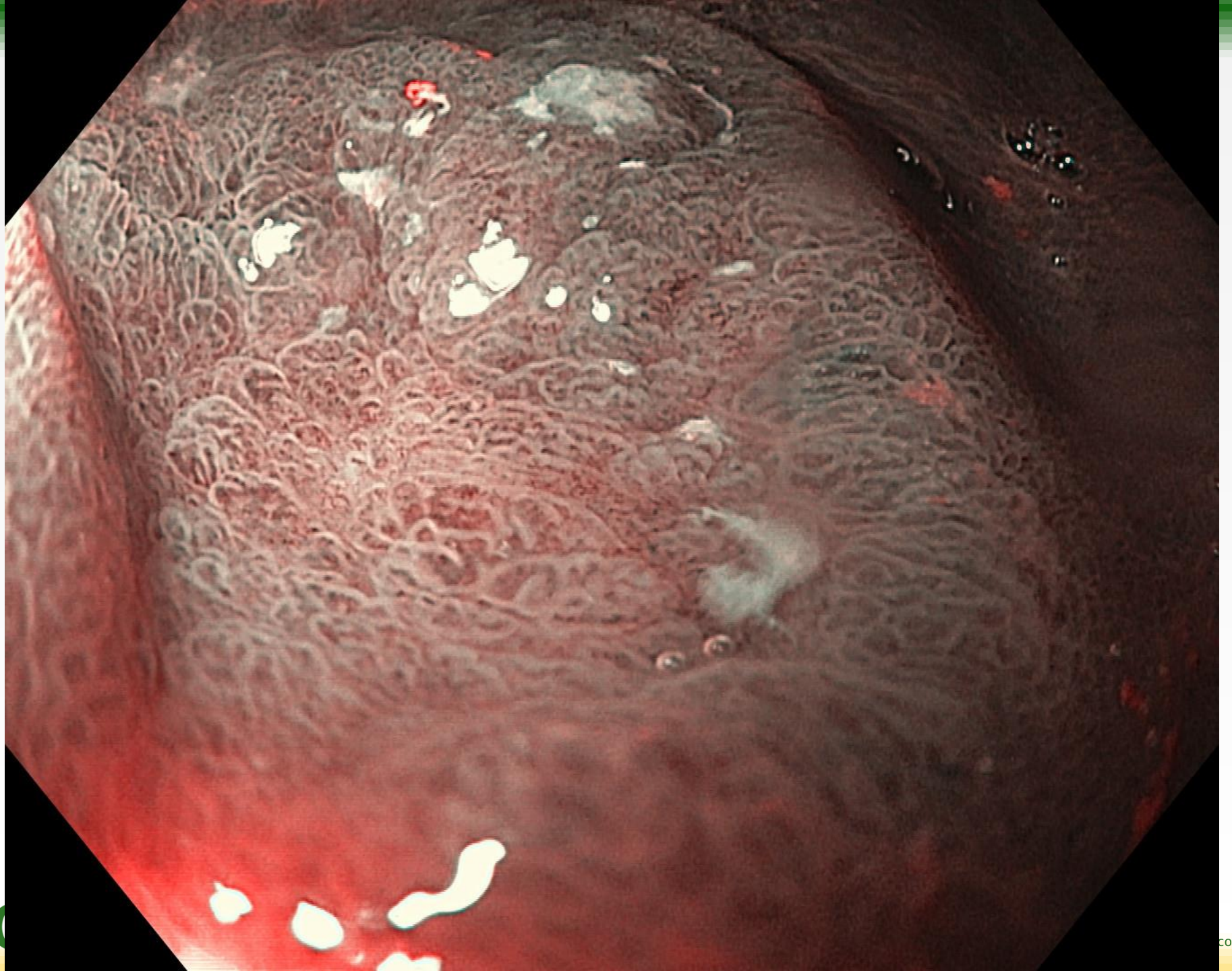
# EXERA III

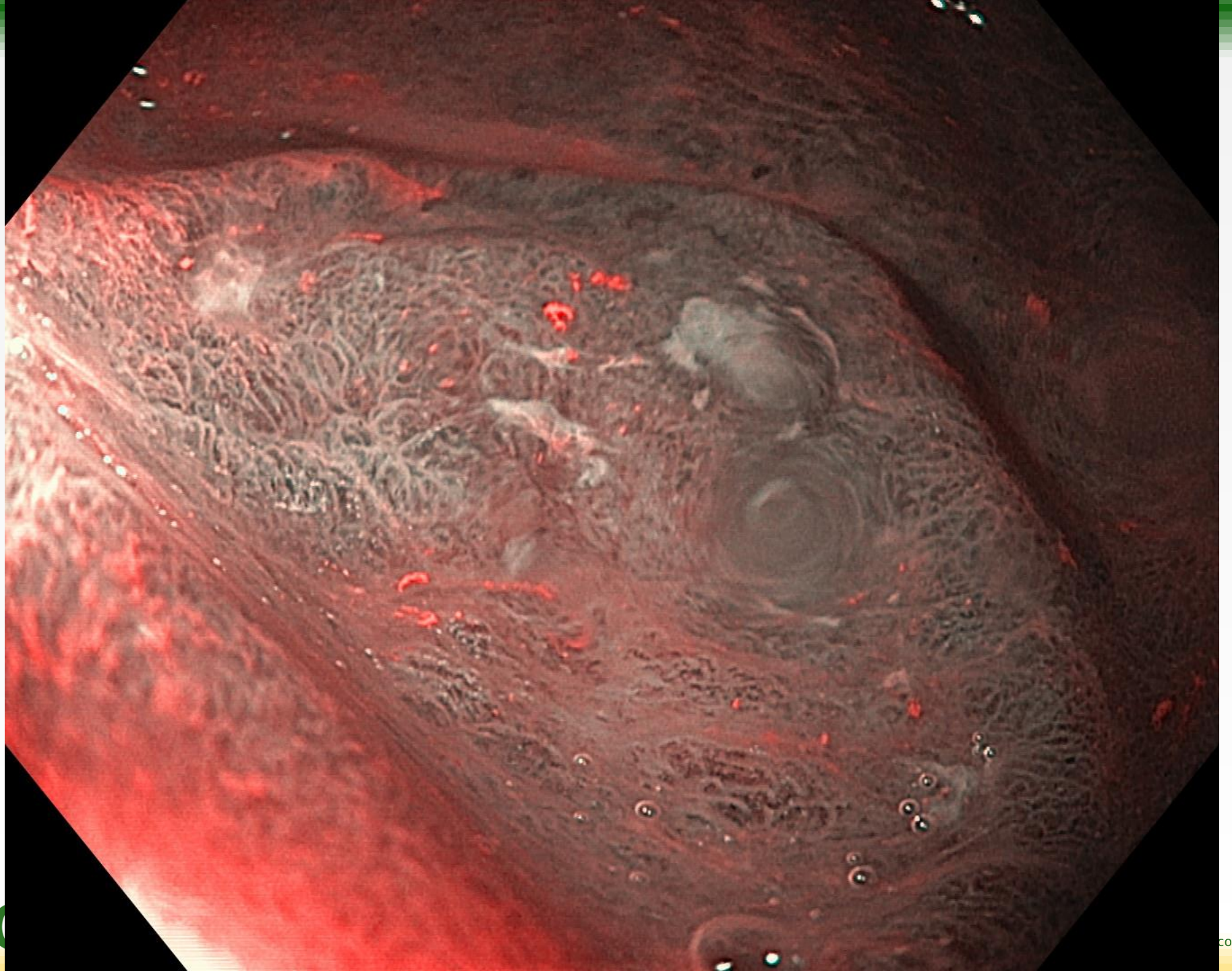


Antral carcinoma

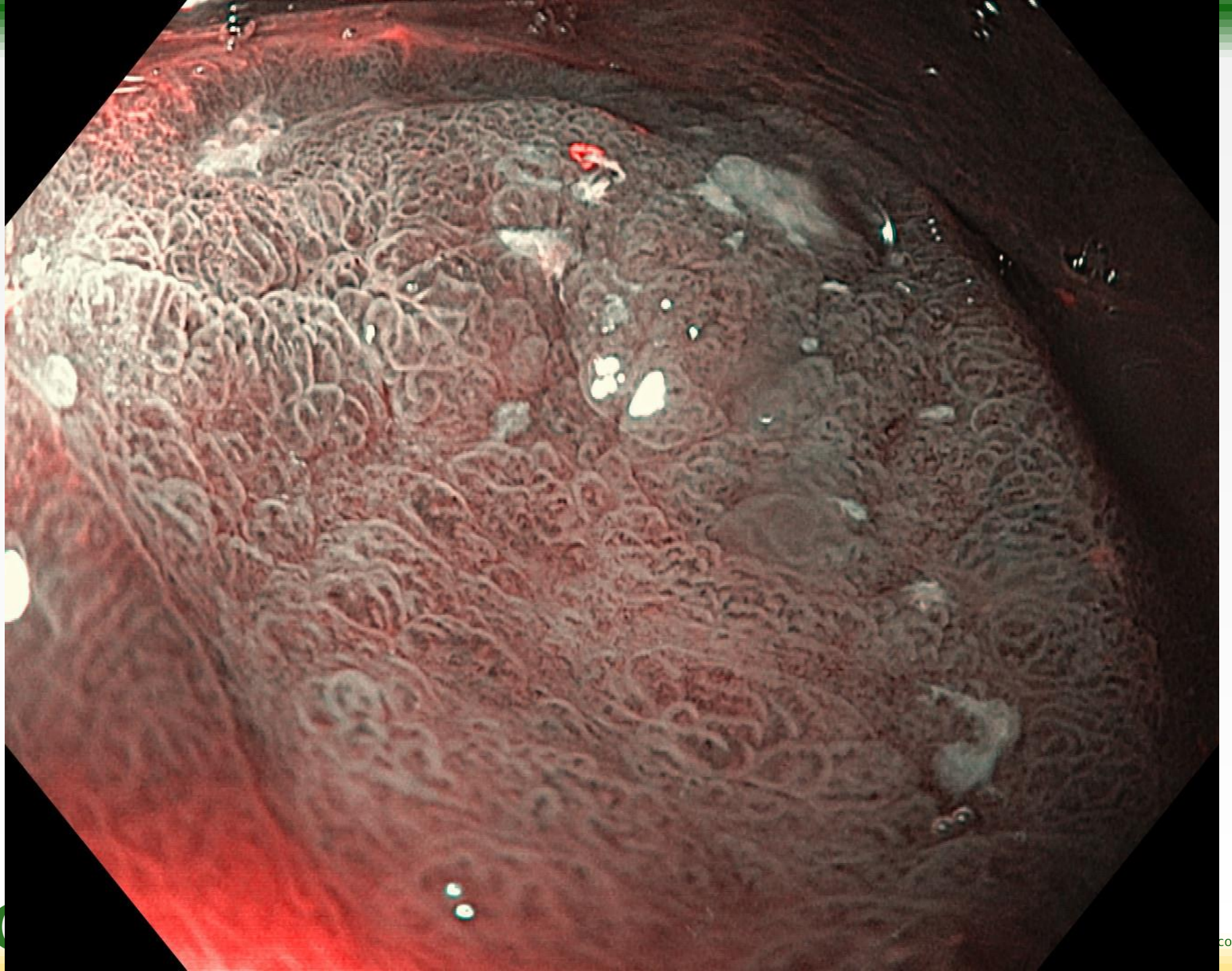


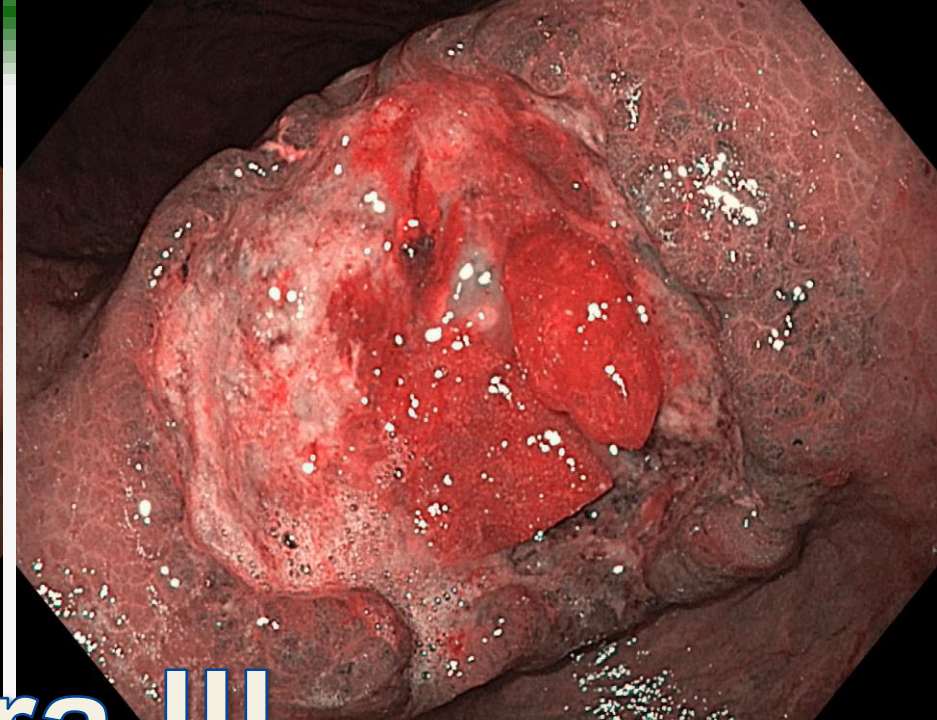
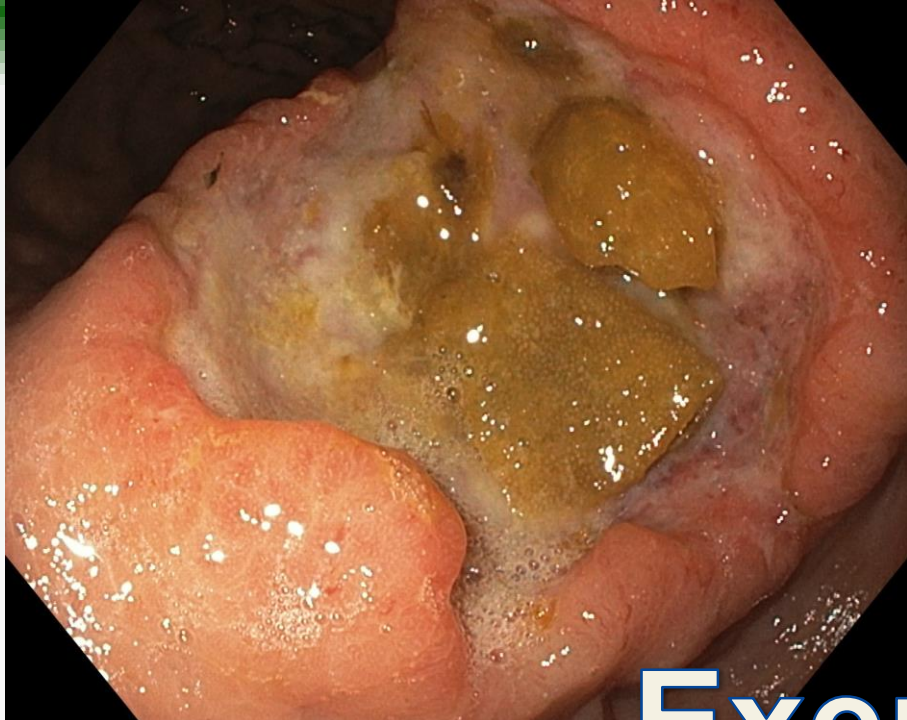


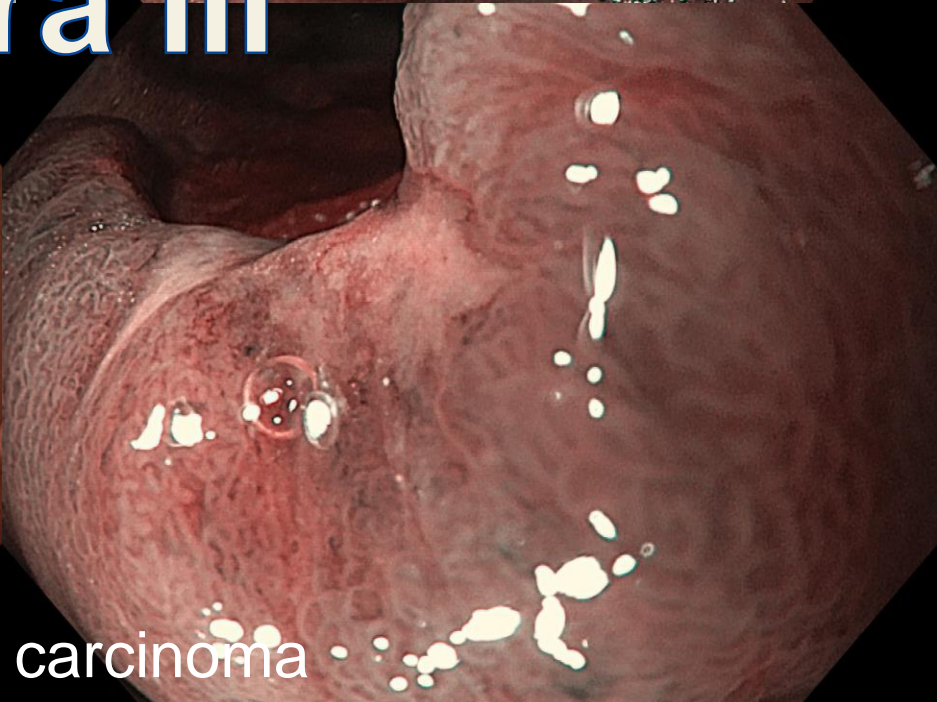
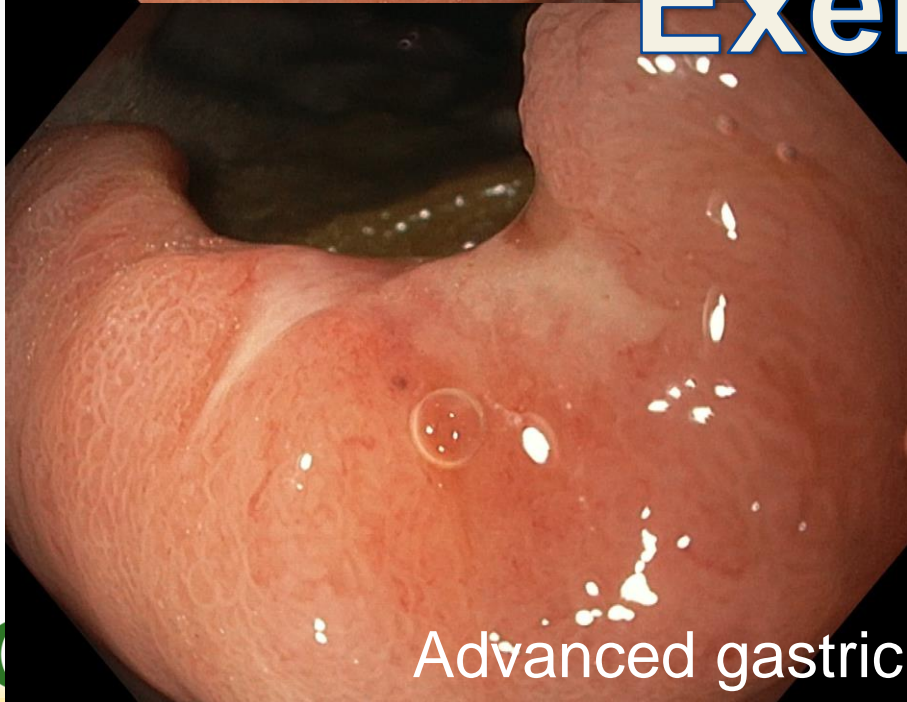




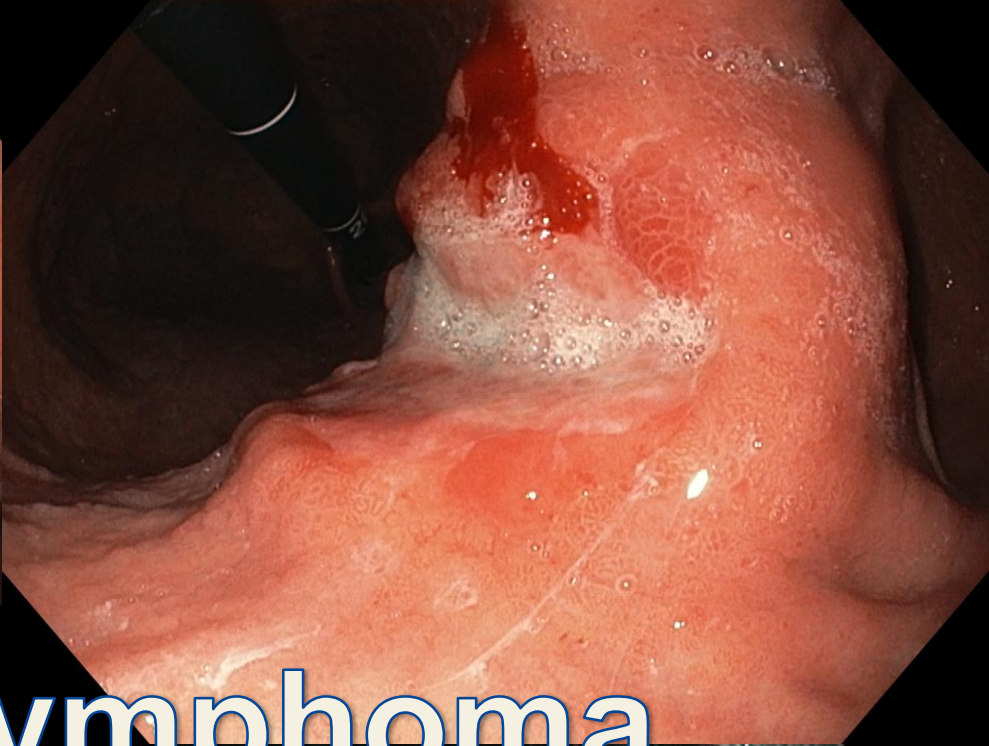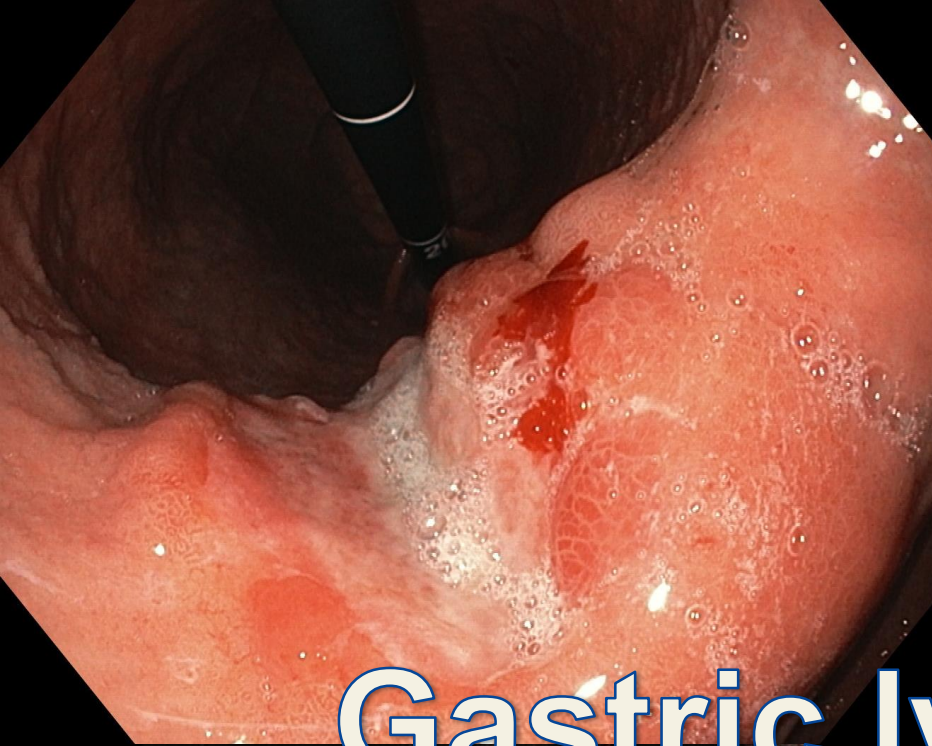




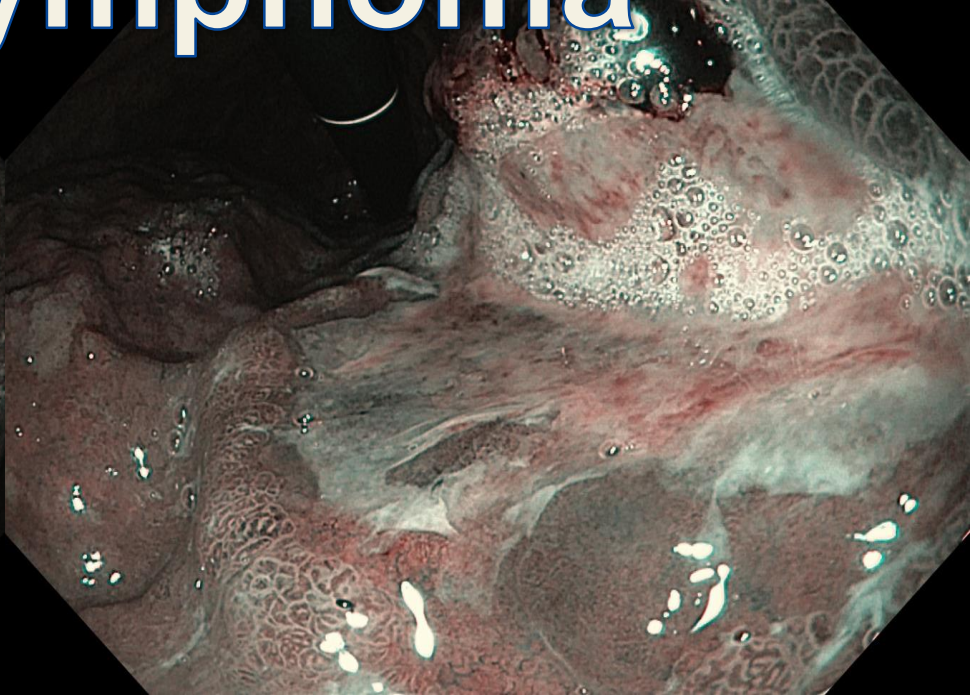
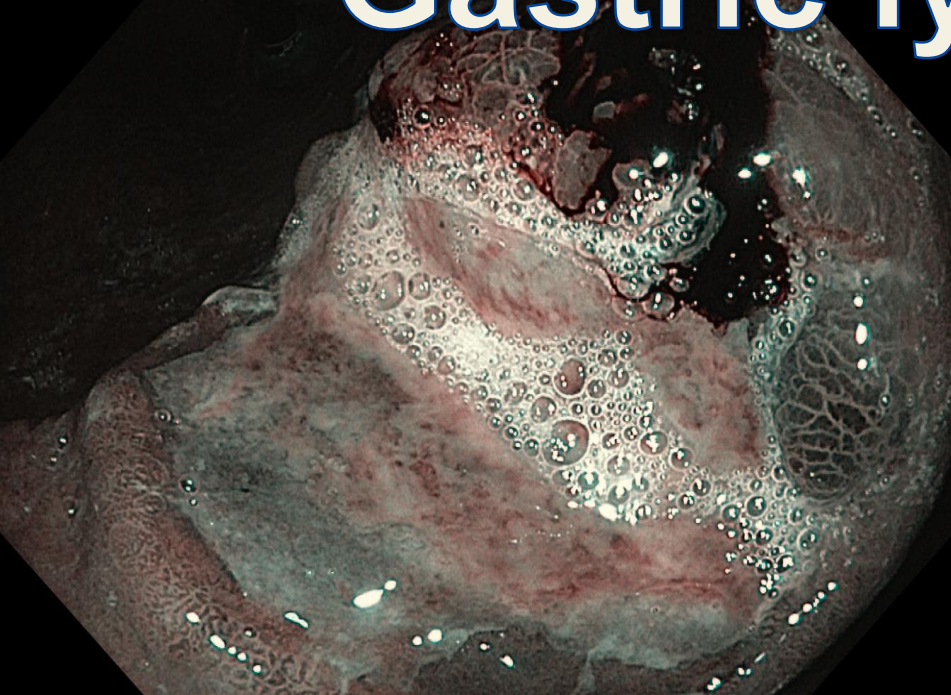
# Exera III

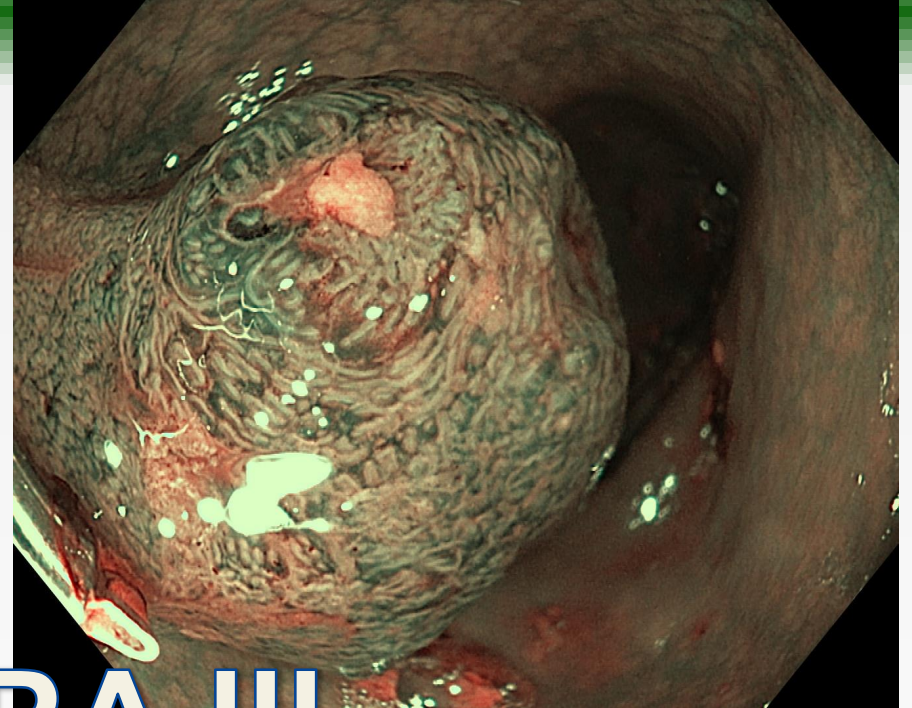
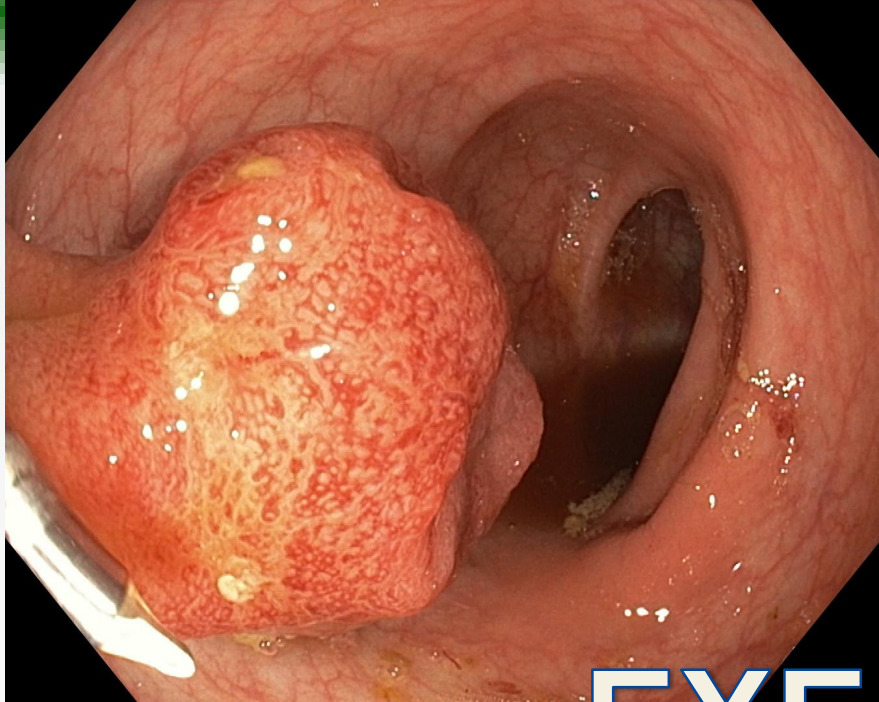


Advanced gastric carcinoma

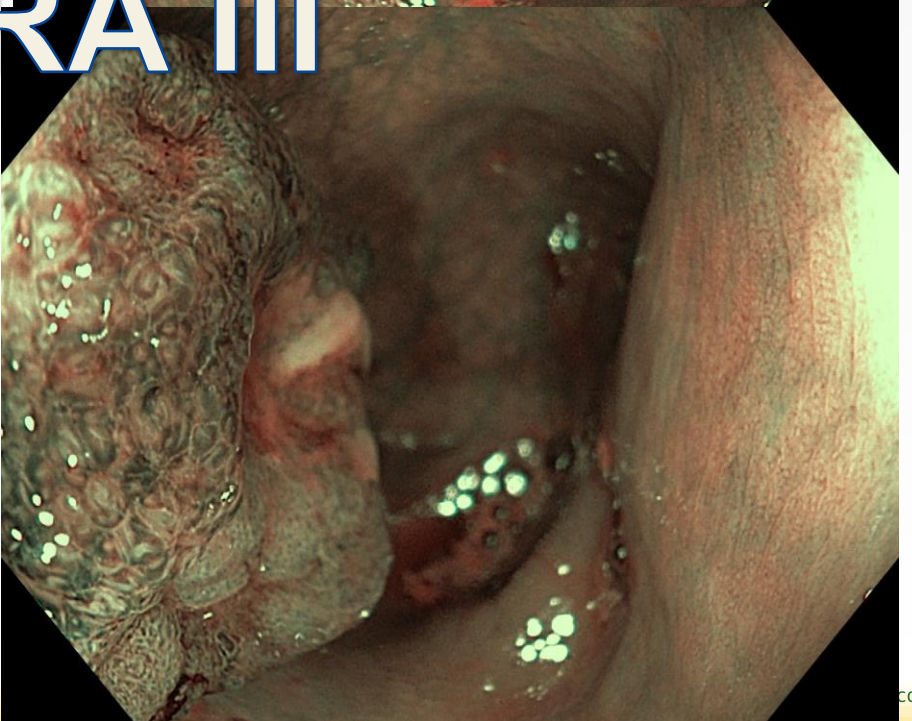
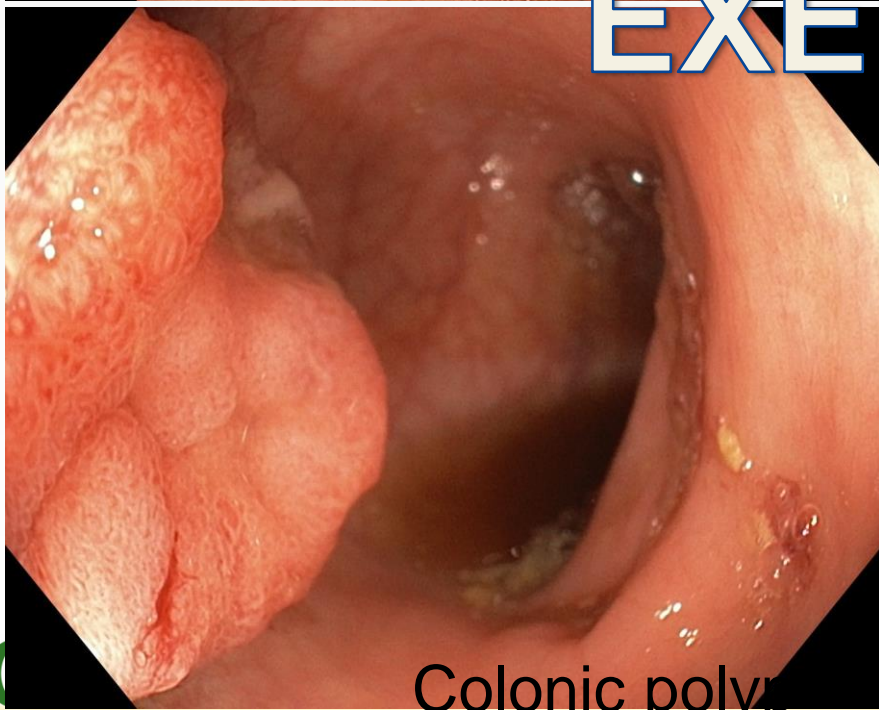


# Gastric lymphoma

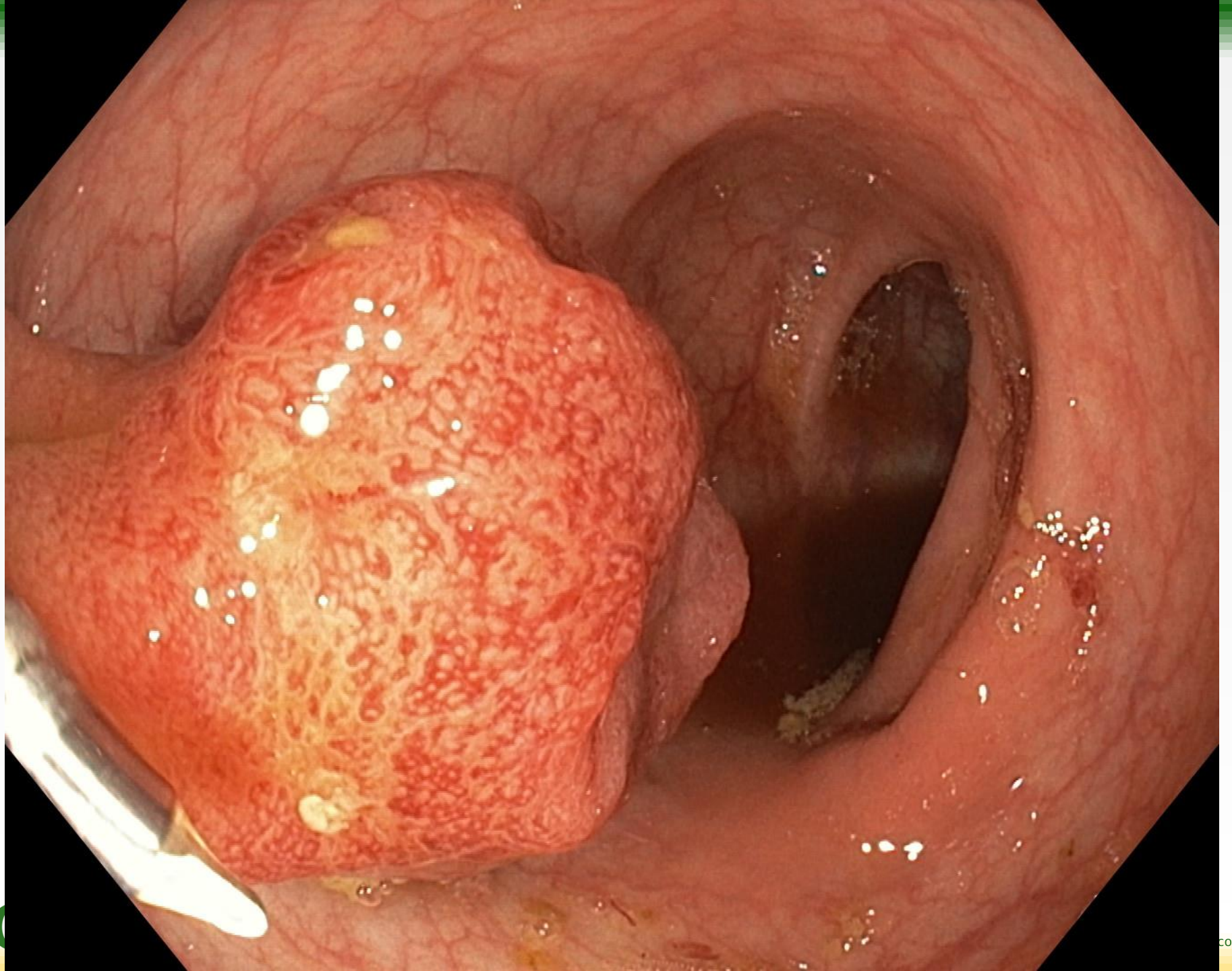


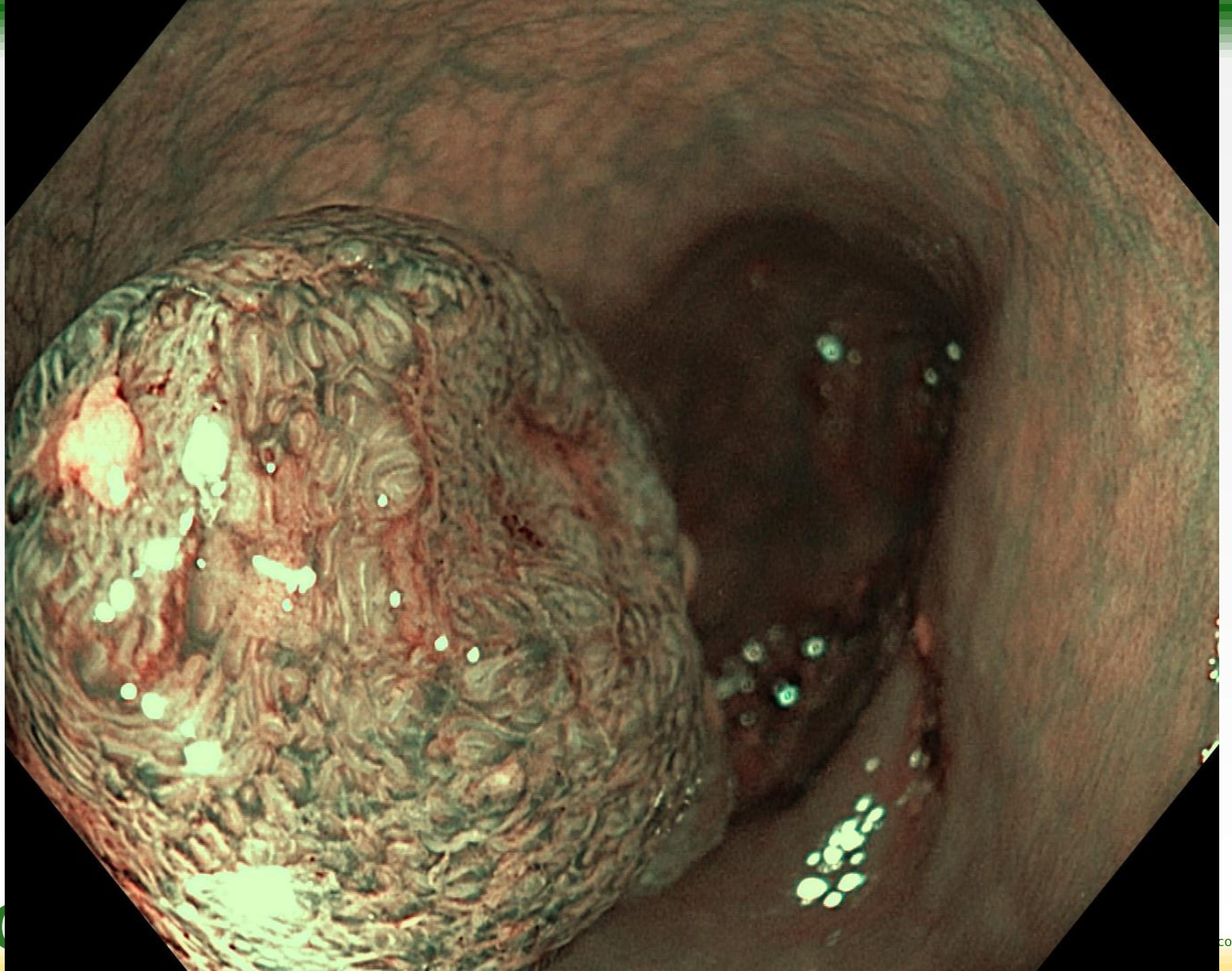


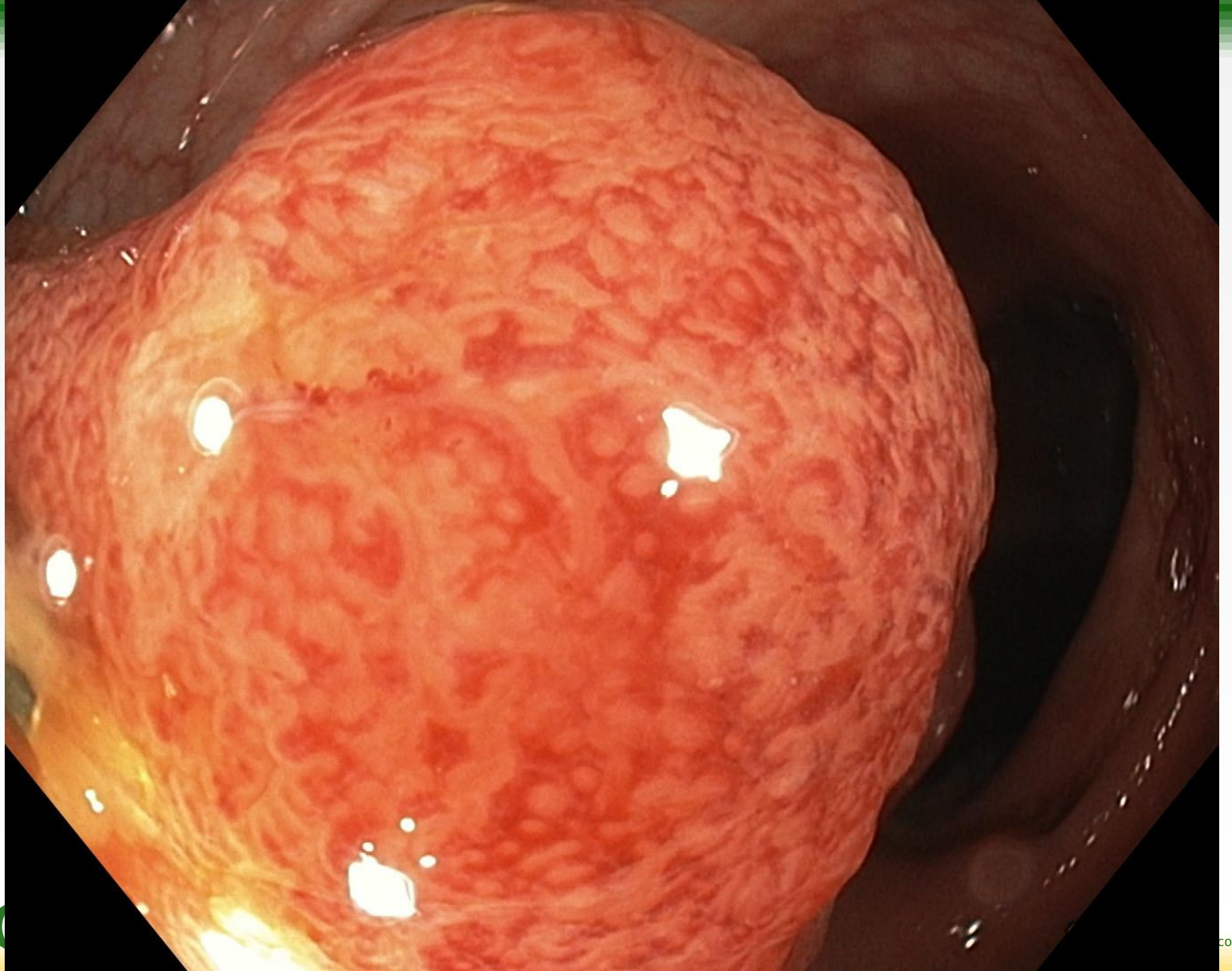
# EXERA III

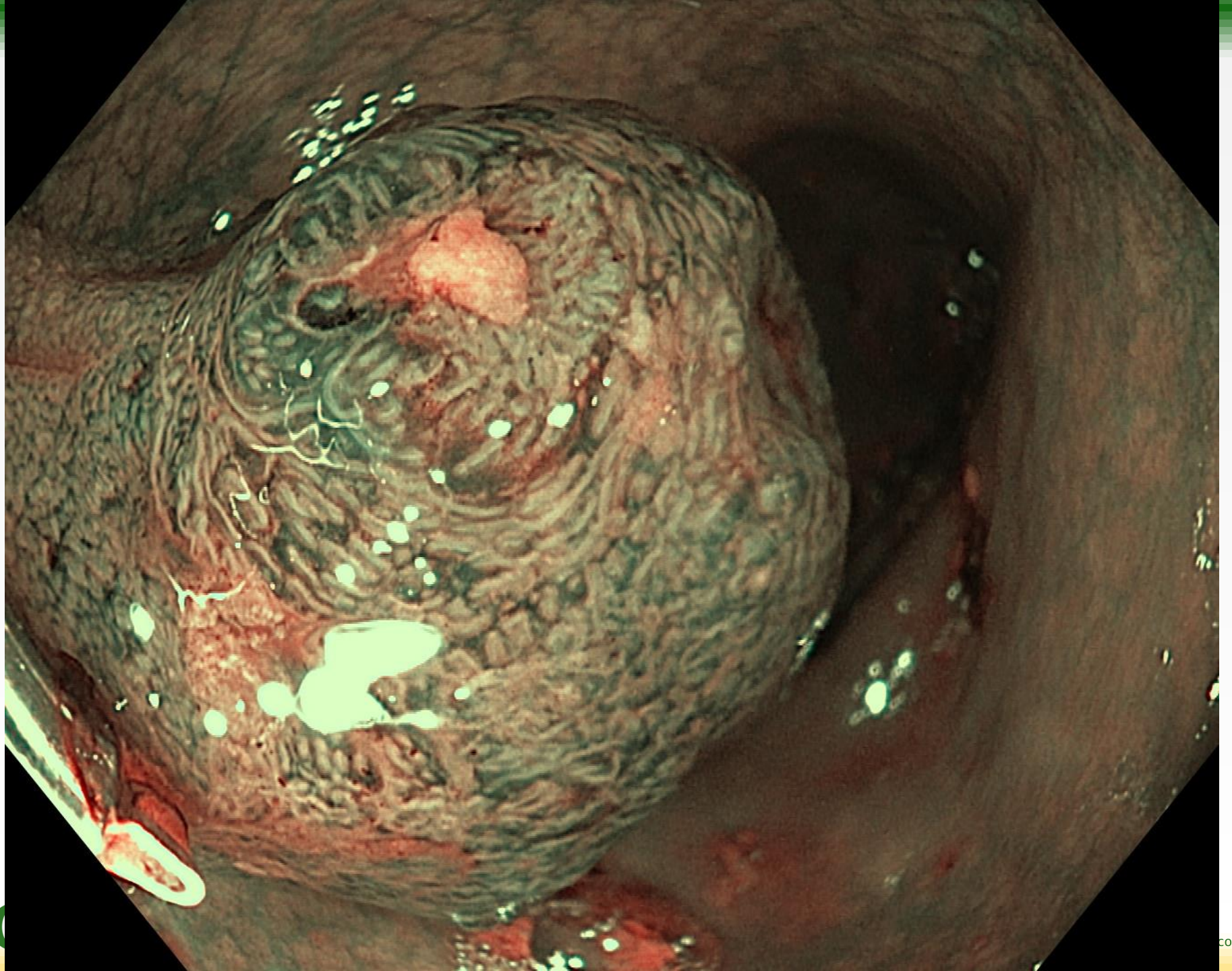


Colonic polyp

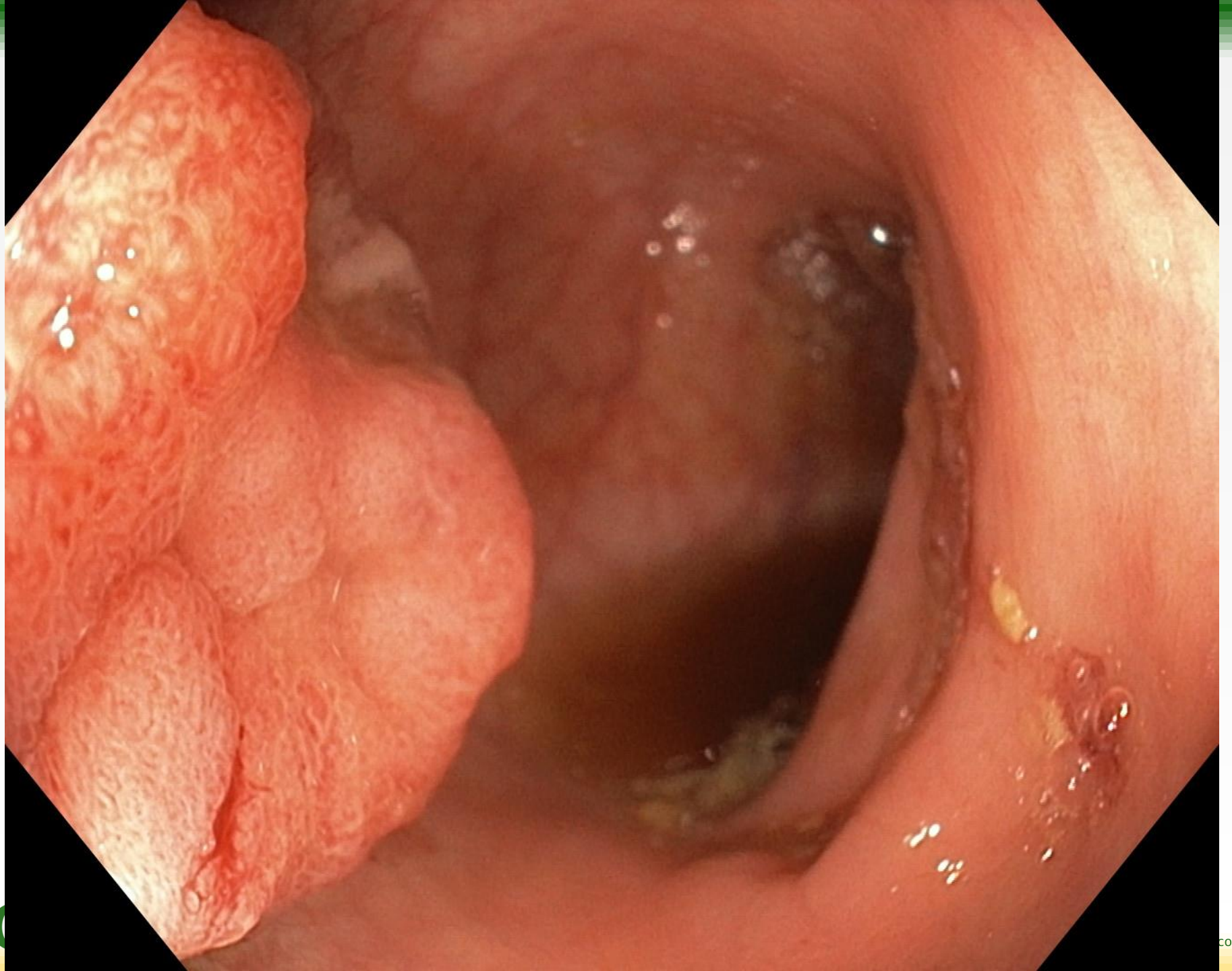


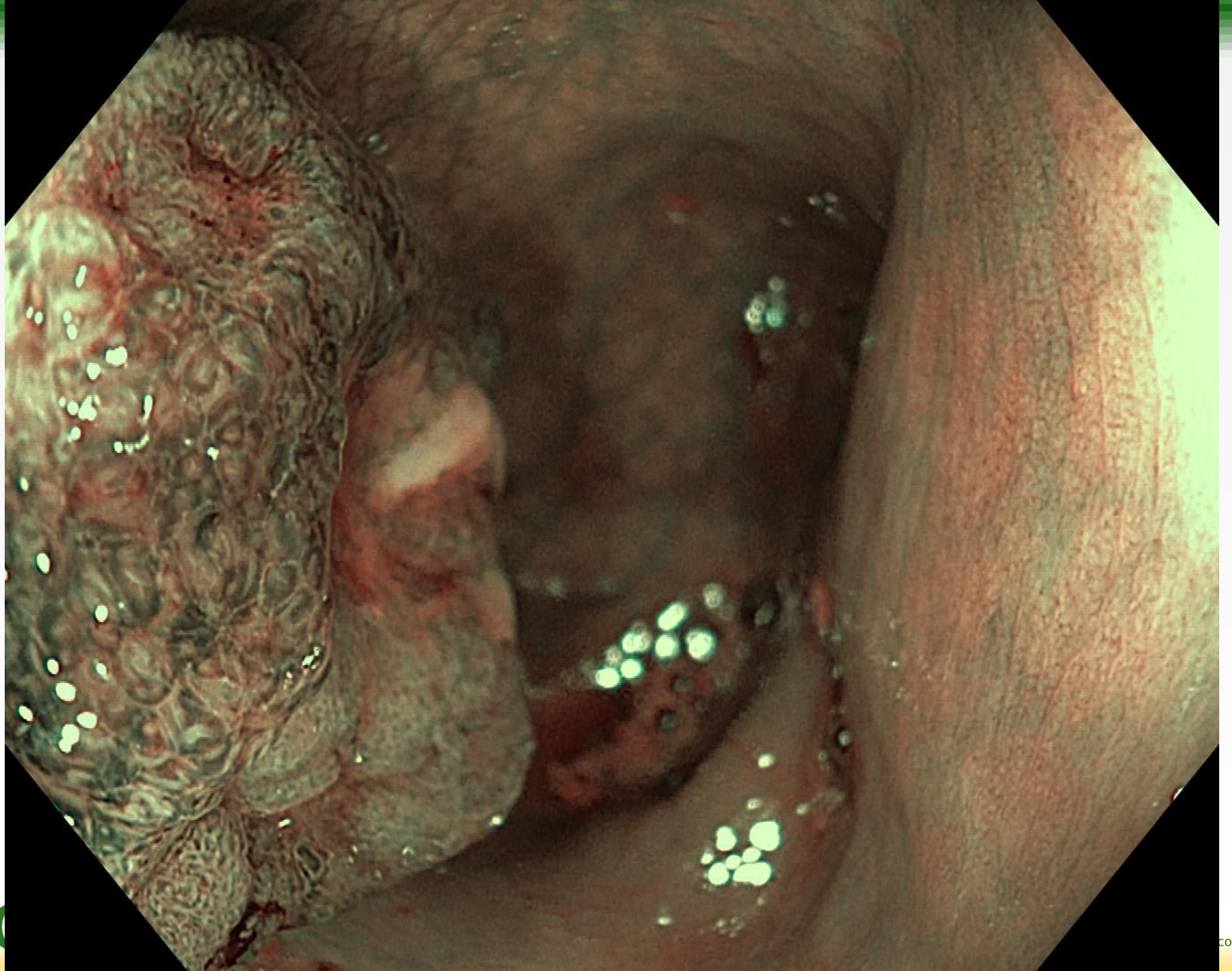










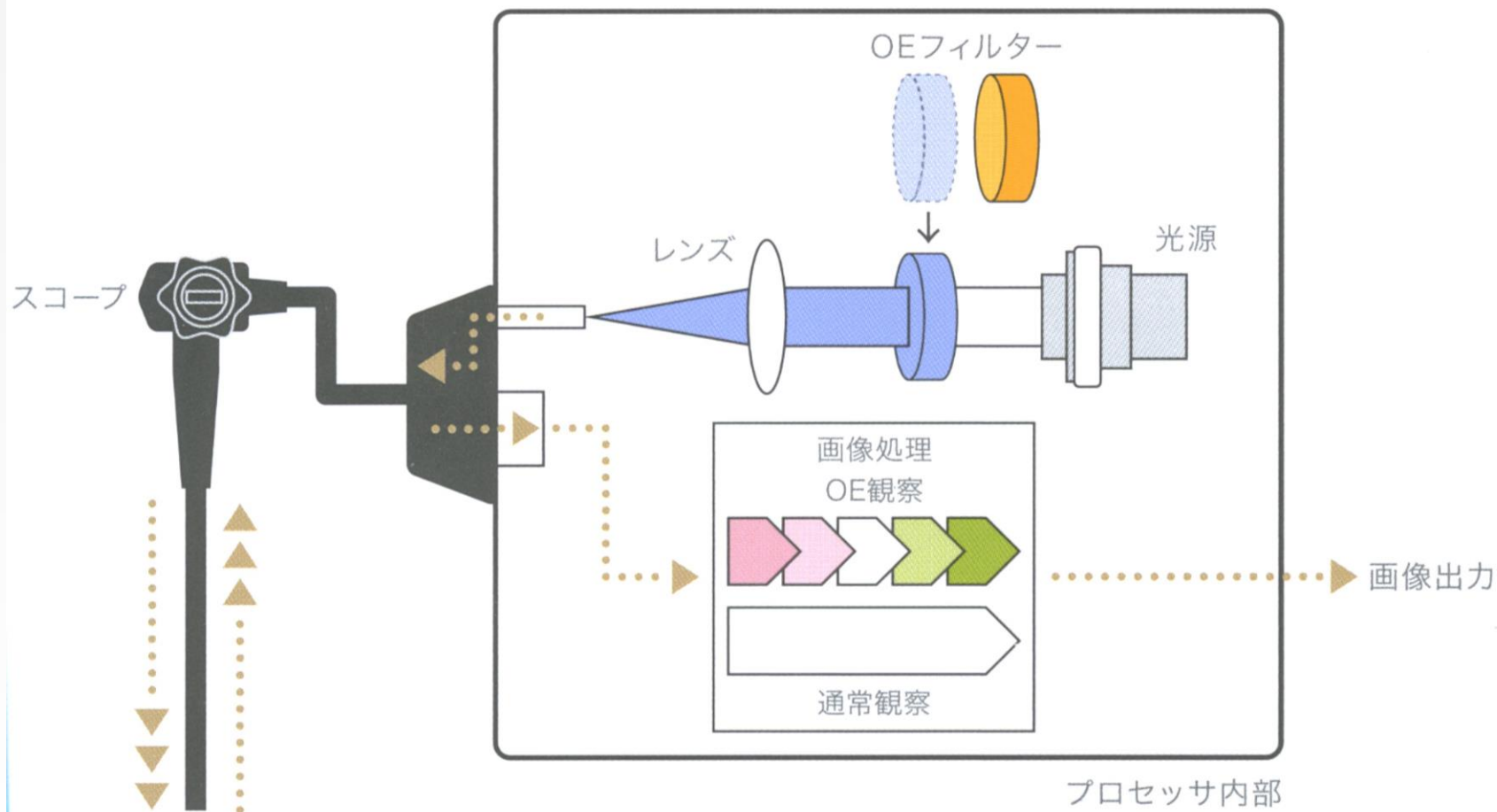


# Optical Enhance (OE - Pentax)

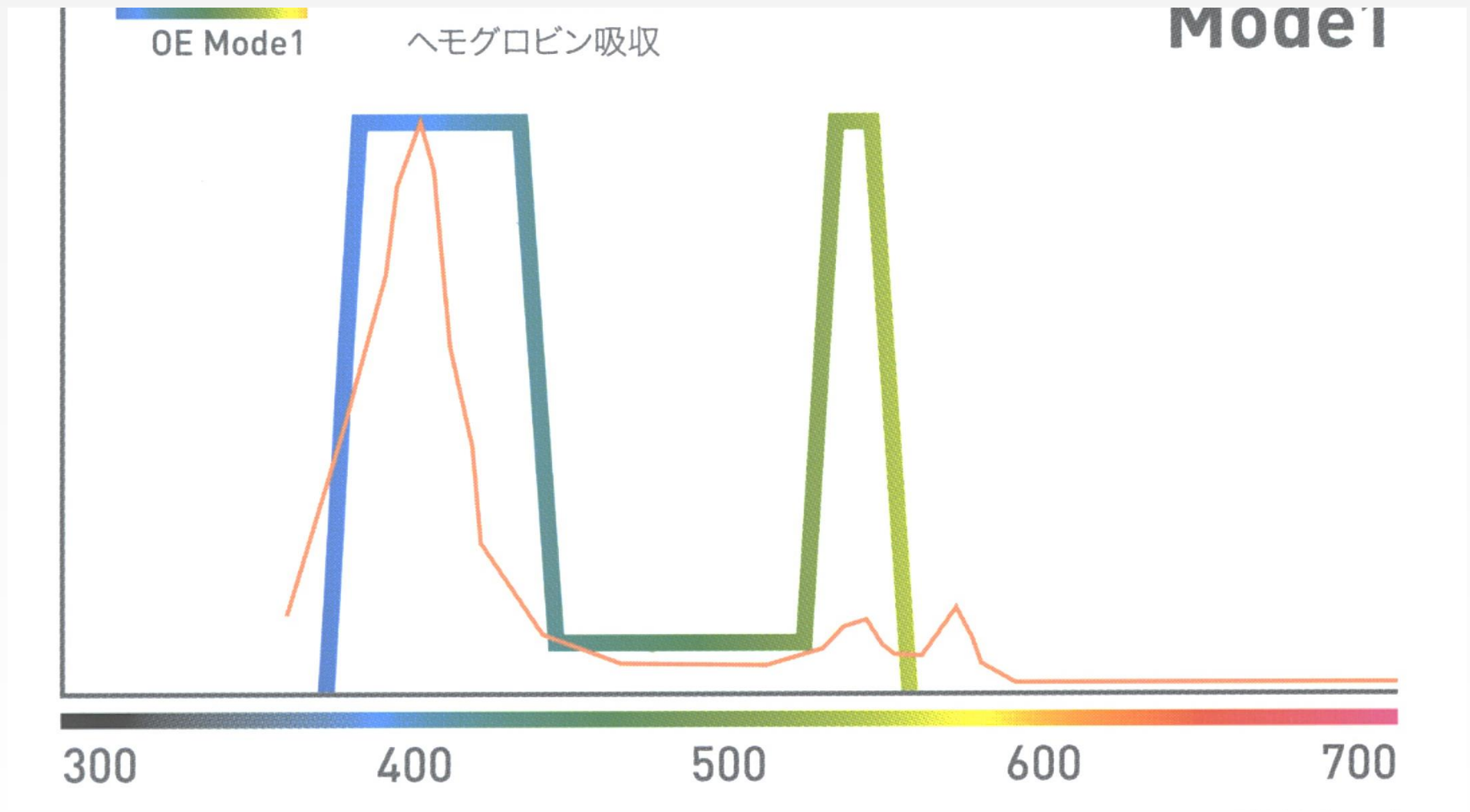
- Different from I-Scan
- OPTICAL TECHNOLOGY very similar from NBI or BLI
  - mode 1 : blue and green filters (as NBI and BLI)
  - mode 2 : enhanced white light for improved detection



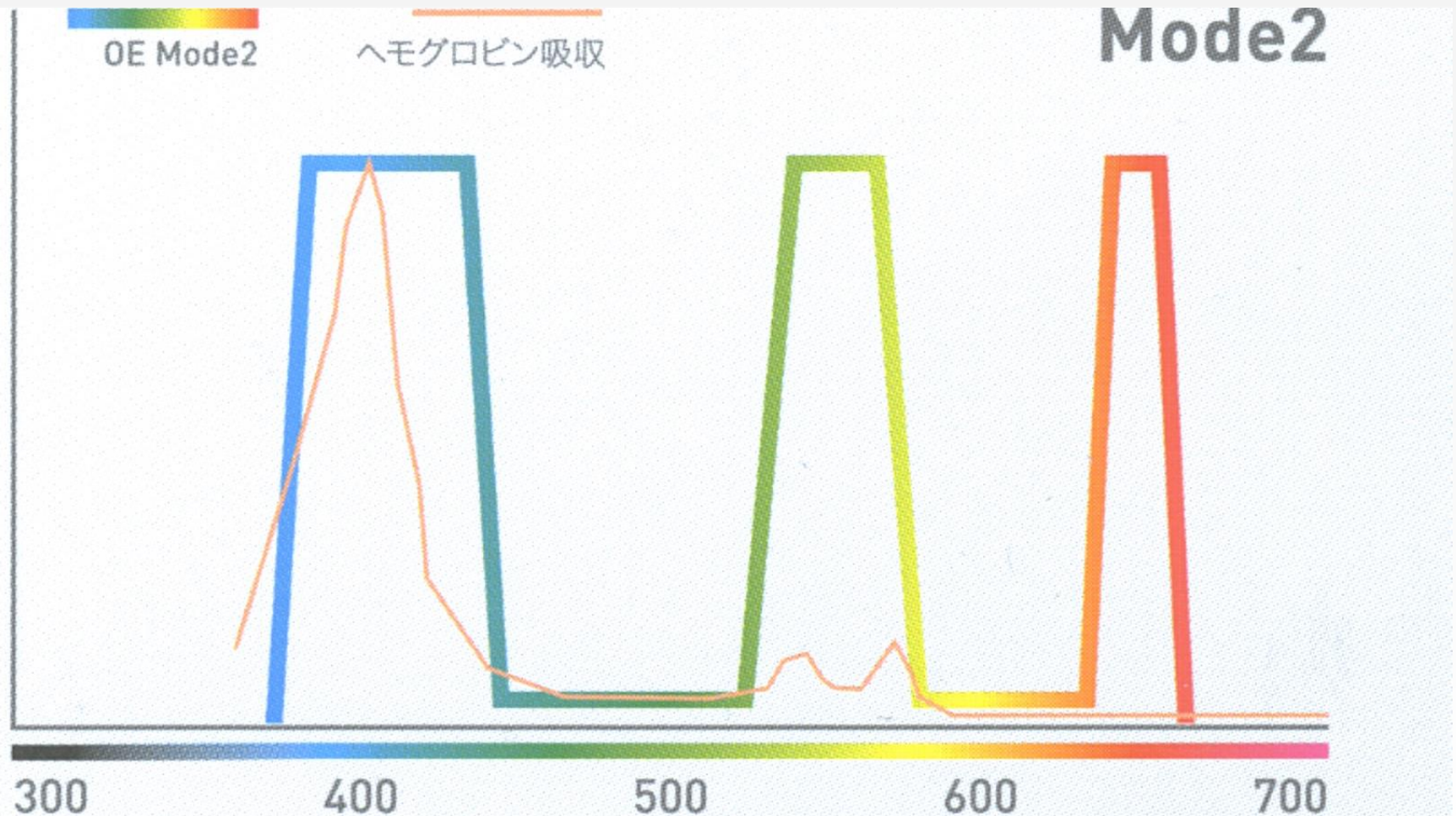
# Optical Enhance



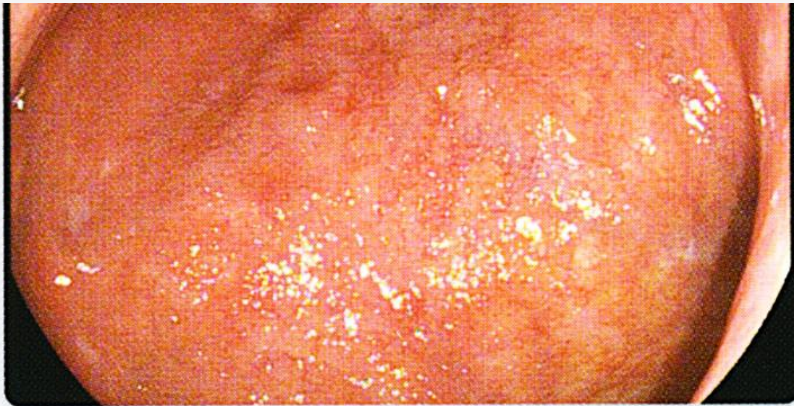# Optical Enhance mode1



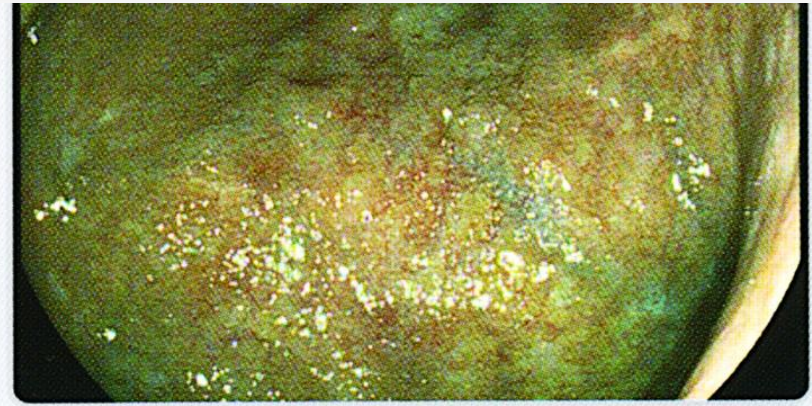
# Optical Enhance mode 2



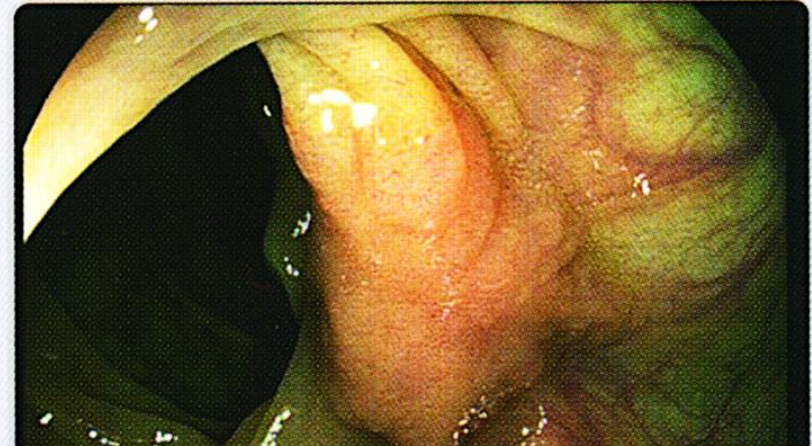
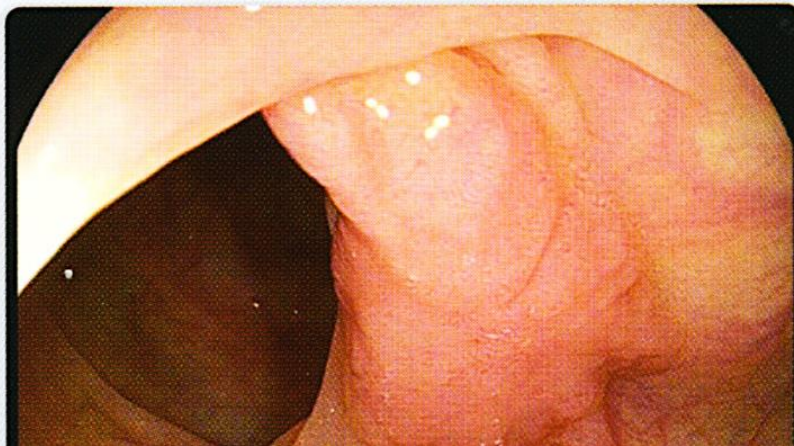# Optical enhancement



通常画像



TE画像



# Blue Laser Imaging (BLI - Fujifilm)

- Totally different from FICE
- New optical development





# BLI versus FICE

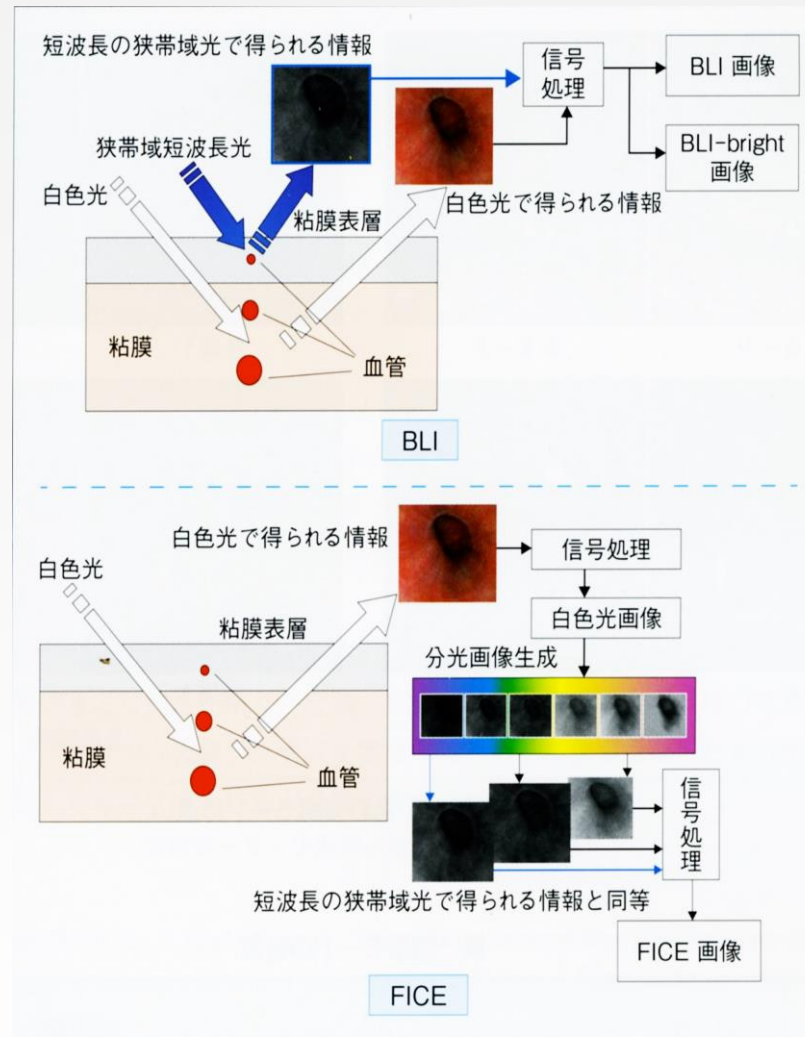


図4 BLI/FICEの処理フロー



# BLI , BLI-bright , FICE

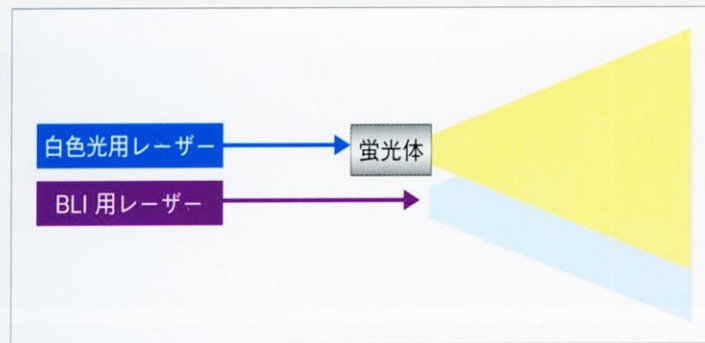


図1 レーザー照明の概念図

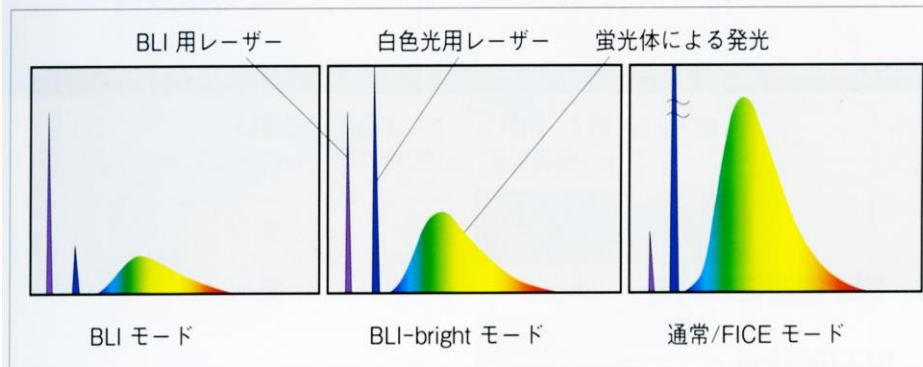


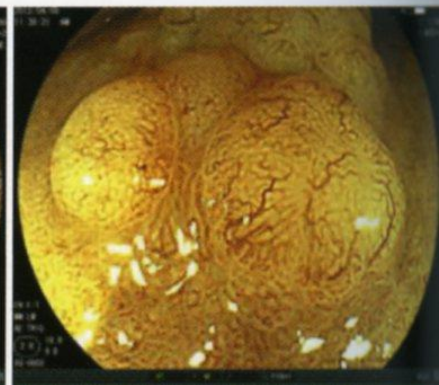
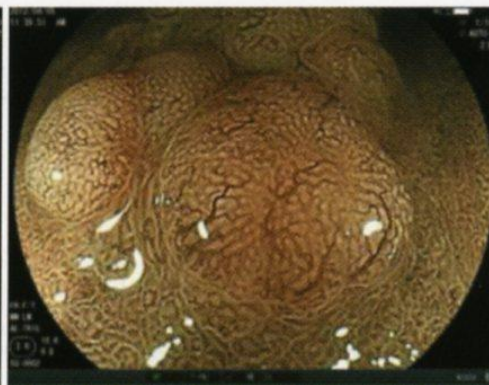
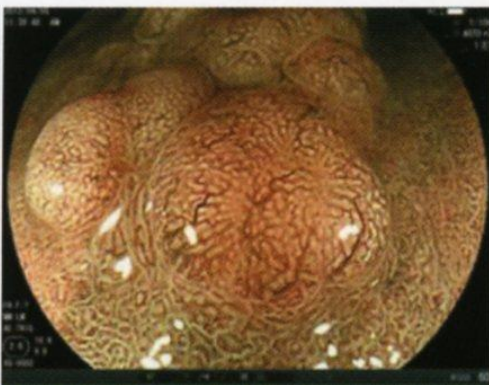
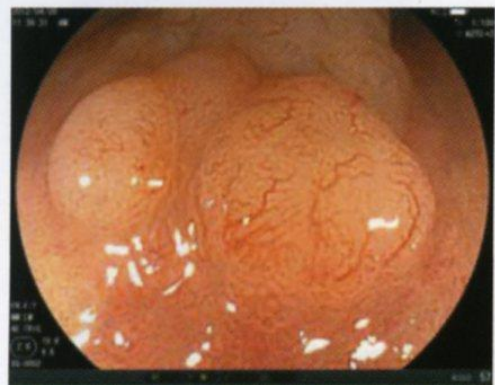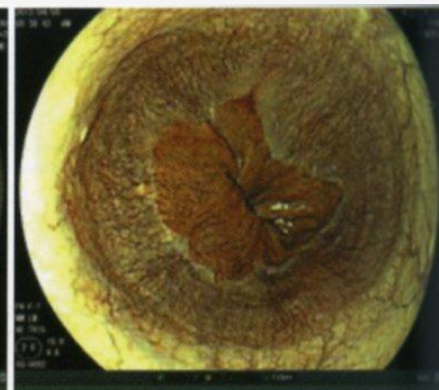
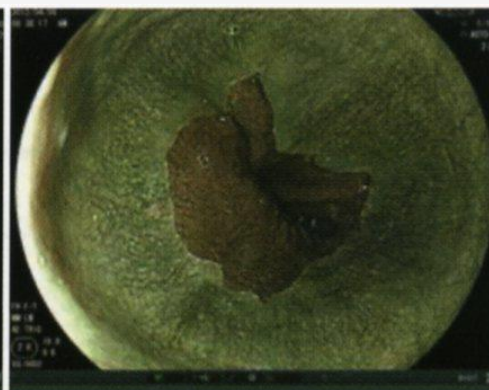
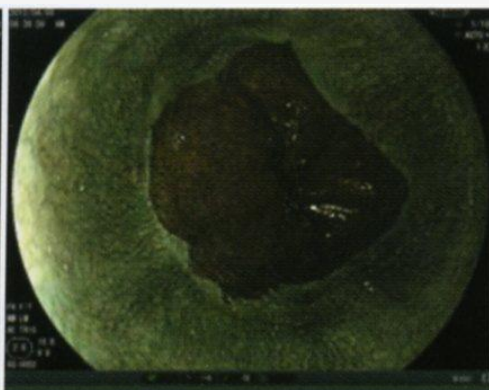
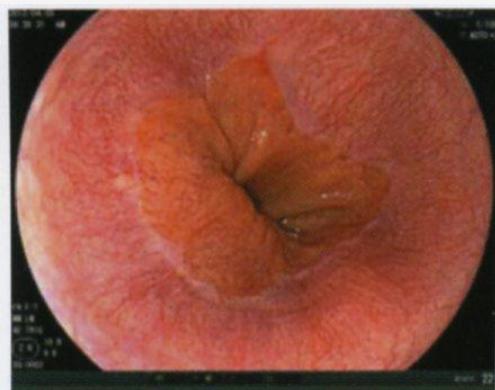
図2 観察モードごとの照明スペクトル

Whit light

BLI

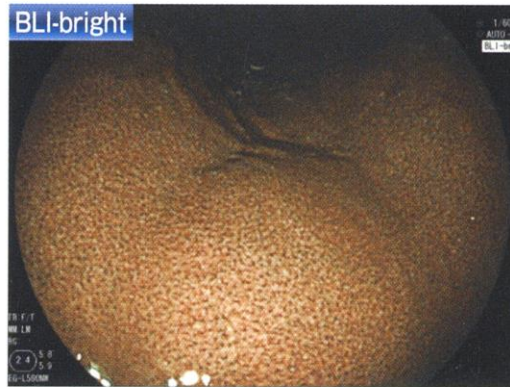
BLI bright

FICE

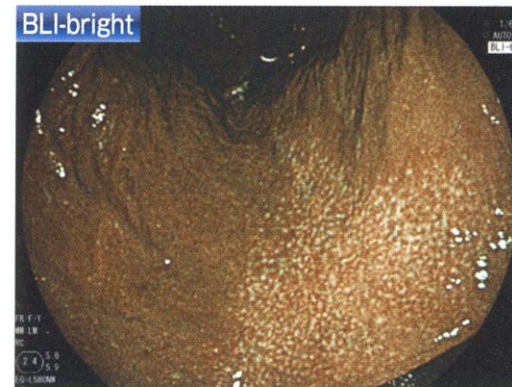

# BLI and BLI-bright

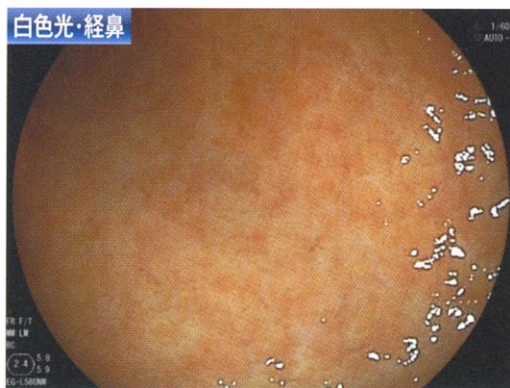## LASEREO臨床画像



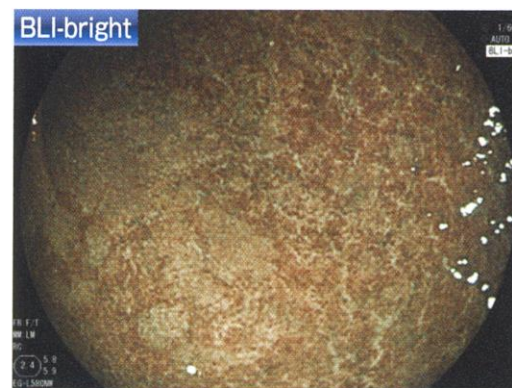
BLI-brightで観察したRAC



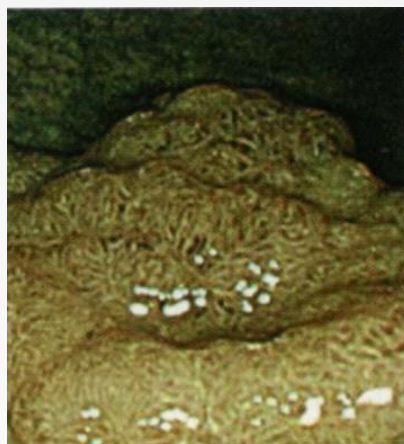BLI-bright観察で萎縮腺境界が明瞭に観察できる



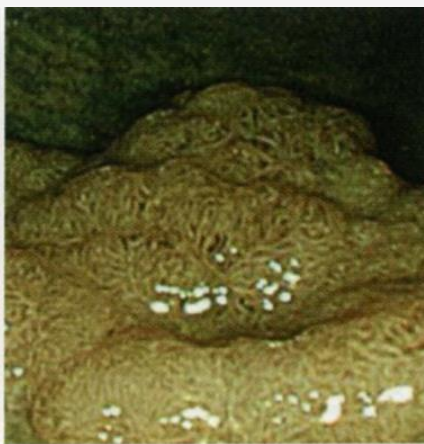白色光で観察した前庭部大弯(左図)、BLI-brightで観察すると腸上皮化生は淡い緑色調結節として観察される



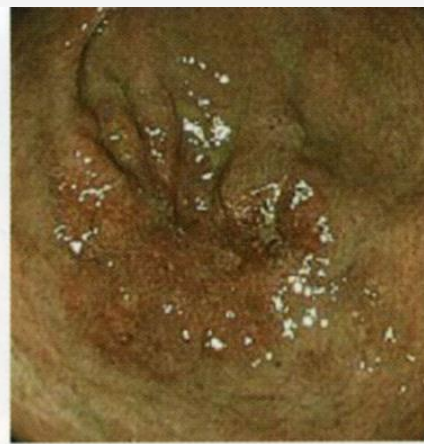# BLI with optical magnification



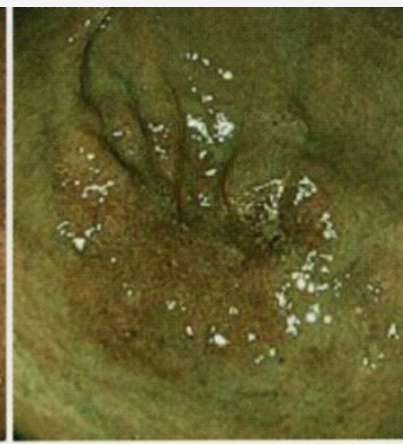
Aモード



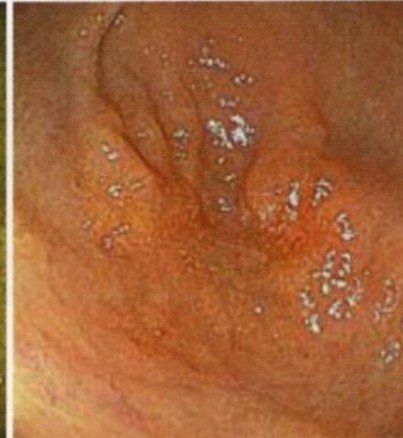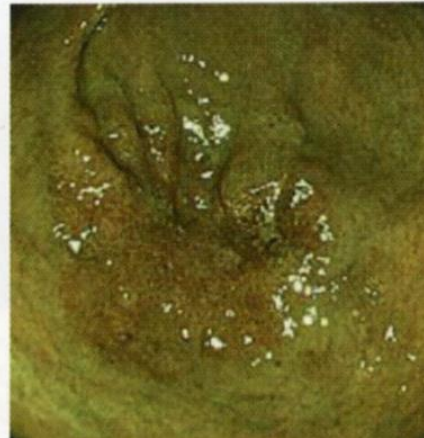
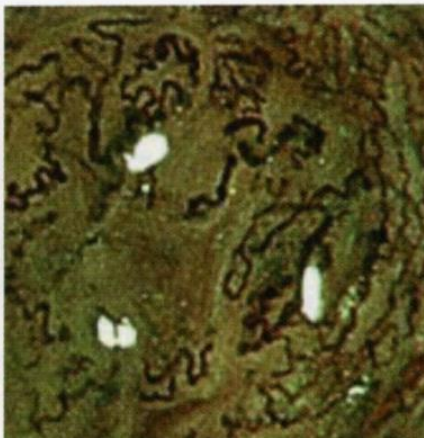
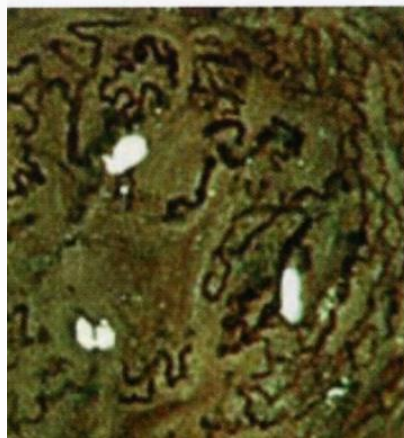
Bモード



色調1



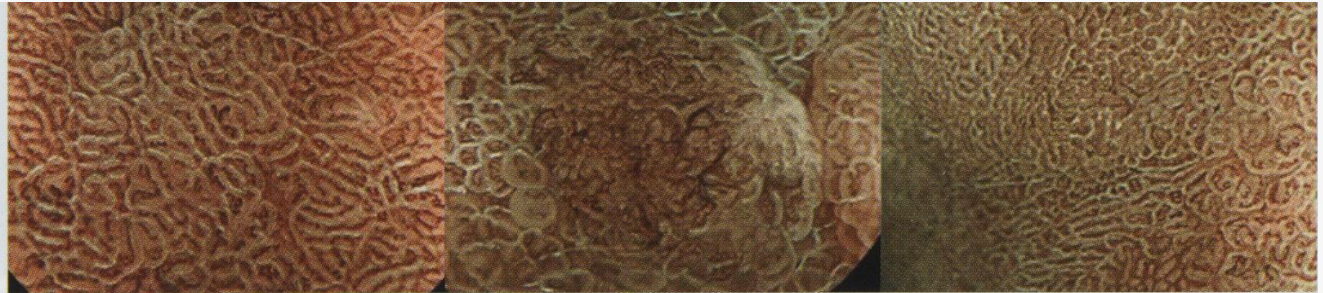
色調2



# Blue Laser Imaging

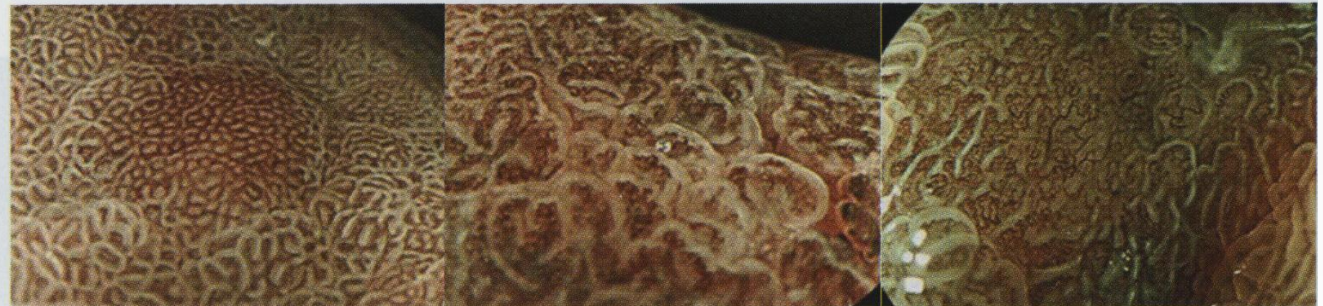
## MV pattern

Regular/Irregular/absent



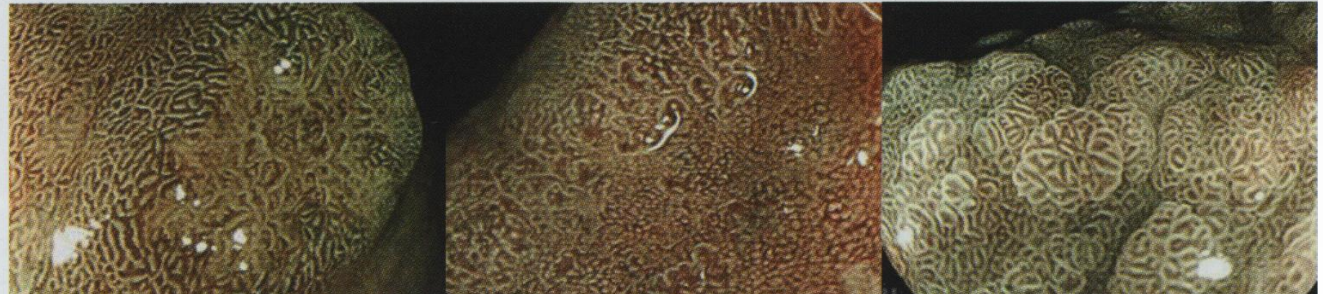
## MS pattern

Regular/Irregular/absent



## DL

demarcation +/+/-



# Clinical benefit of NBI et related techniques

- Alternative to traditional chromoscopy
- Endoscopic assessment :
  - mucosal structure (pit pattern classification)
  - vascular superficial network
- **Easy to carry on !**

